

## Adverse events of upper GI endoscopy

*This is one of a series of statements discussing the use of GI endoscopy in common clinical situations. The Standards of Practice Committee of the American Society for Gastrointestinal Endoscopy (ASGE) prepared this text. In preparing this document, a search of the medical literature was performed by using PubMed. Additional references were obtained from the bibliographies of the identified articles and from recommendations of expert consultants. When few or no data exist from well-designed prospective trials, emphasis is given to results of large series and reports from recognized experts. This document is based on a critical review of the available data and expert consensus at the time that the document was drafted. Further controlled clinical studies may be needed to clarify aspects of this document. This document may be revised as necessary to account for changes in technology, new data, or other aspects of clinical practice.*

*This document is intended to be an educational device to provide information that may assist endoscopists in providing care to patients. This document is not a rule and should not be construed as establishing a legal standard of care or as encouraging, advocating, requiring, or discouraging any particular treatment. Clinical decisions in any particular case involve a complex analysis of the patient's condition and available courses of action. Therefore, clinical considerations may lead an endoscopist to take a course of action that varies from this document.*

Upper GI (UGI) endoscopy is commonly performed and carries a low risk of adverse events. Large series report adverse event rates of 1 in 200 to 1 in 10,000 and mortality rates ranging from none to 1 in 2000.<sup>1-6</sup> Data collected from the Clinical Outcomes Research Initiative database show a cardiopulmonary event rate of 1 in 170 and a mortality rate of 1 in 10,000 from among 140,000 UGI endoscopic procedures.<sup>7</sup> The variability in rates of adverse events may be attributed to the method of data collection, patient populations, duration of follow-up, and definitions of adverse events. Some authors include minor incidents, such as transient hypoxemia or self-limited bleeding as adverse events, whereas others report only significant adverse events that prevent completion of the procedure or result in hospitalization.<sup>8</sup> Additionally, the majority of pub-

lications rely on self-reporting, and most reported data collected only from the immediate periprocedure period, thus the rate of late adverse events and mortality may be underestimated.<sup>8,9</sup> Major adverse events related to diagnostic UGI endoscopy are rare and include cardiopulmonary adverse events, infection, perforation, and bleeding. Adverse events of ERCP and EUS are discussed in separate ASGE documents.<sup>10,11</sup>

### ADVERSE EVENTS ASSOCIATED WITH DIAGNOSTIC UGI ENDOSCOPY

#### Cardiopulmonary adverse events

Most UGI procedures in the United States and Europe are performed with patients under sedation (moderate or deep).<sup>12</sup> Cardiopulmonary adverse events related to sedation and analgesia account for as much as 60% of UGI endoscopy adverse events.<sup>1-4,7</sup> The rate of cardiopulmonary adverse events in large, national studies is between 1 in 170 and 1 in 10,000.<sup>1-4,6,7</sup> Reported adverse events range from minor incidents, such as changes in oxygen saturation or heart rate, to significant adverse events such as aspiration pneumonia, respiratory arrest, myocardial infarction, stroke, and shock. Patient-related risk factors for cardiopulmonary adverse events include preexisting cardiopulmonary disease, advanced age, American Society of Anesthesiologists class III or higher, and an increased modified Goldman score.<sup>13,14</sup> Procedure-related risk factors for hypoxemia include difficulty with intubating the esophagus, a prolonged procedure, and a patient in the prone position.<sup>7,8,15,16</sup> For a detailed discussion and specific recommendations, the reader is referred to the ASGE document "Sedation and Anesthesia in GI Endoscopy"<sup>17</sup> and the "American Society of Anesthesiology Practice Guidelines for Sedation and Analgesia by Nonanesthesiologists."<sup>18</sup>

#### Infectious adverse events

Infectious adverse events of diagnostic UGI endoscopy can result from either the procedure itself or failure to follow guidelines for the reprocessing and use of endoscopic devices and accessories.<sup>19,20</sup> Transient bacteremia as a result of diagnostic UGI endoscopy has been reported at rates as high as 8%, but the frequency of infectious endocarditis and other clinical sequelae is extremely low.<sup>21,22</sup> Current American Heart Association and ASGE guidelines do not recommend antibiotic prophylaxis with

diagnostic UGI endoscopy solely to prevent infectious endocarditis.<sup>20,23</sup>

### Perforation

Prospective, multicenter registries report perforation rates of 1 in 2500 to 1 in 11,000.<sup>4,24</sup> Factors predisposing to perforation include the presence of anterior cervical osteophytes, Zenker's diverticulum, esophageal stricture, malignancies of the UGI tract, and duodenal diverticula.<sup>24,25</sup> Perforation of the esophagus is associated with a mortality rate between 2% and 36%.<sup>26-29</sup> Early identification and expeditious management of a perforation have been shown to decrease associated morbidity and mortality.<sup>29,30</sup>

### Bleeding

Clinically significant bleeding is a rare adverse event of diagnostic UGI endoscopy.<sup>31</sup> Mallory-Weiss tears occur in less than 0.5% of diagnostic UGI endoscopic procedures and usually are not associated with significant bleeding.<sup>32</sup> Bleeding may be more likely in individuals with thrombocytopenia and/or coagulopathy.<sup>1</sup> The minimum threshold platelet count for the performance of diagnostic UGI endoscopy has not been established. UGI endoscopy with biopsy was shown to be safe in 1 study of adults with solid malignancies and platelet counts greater than 20,000/mL.<sup>33</sup> Two case series of UGI endoscopy with or without biopsies in children with platelet counts greater than 50,000/mL reported no bleeding adverse events.<sup>34,35</sup> However, a larger study of 198 UGI endoscopies in children after stem cell transplantation demonstrated that the risk of bleeding requiring red blood cell transfusions after UGI endoscopic biopsies was 4% despite a minimum platelet count of 50,000/mL.<sup>36</sup> Four of these 8 patients were found to have duodenal hematomas. Thus, some authors have concluded that diagnostic UGI endoscopy can be performed when the platelet level is 20,000/mL or greater and that a threshold of 50,000/mL should be considered before performing biopsies.<sup>37-40</sup>

## ADVERSE EVENTS OF ENDOSCOPIC INTERVENTIONS

### Adverse events of UGI dilation

Data from randomized trials and large case series suggest that the overall rate of dilation adverse events is between 0.1% and 0.4%.<sup>1,41-44</sup> The most common adverse events are perforation, hemorrhage, aspiration, and bacteremia. Most dilation-related bleeding is self-limited, but rare episodes of bleeding requiring endoscopic hemostasis and dissection into major blood vessels have been reported.<sup>45,46</sup> Patients with significant obstruction of the UGI tract may be at risk of aspiration of retained food and fluid. In these situations, measures to avoid aspiration should be considered (eg, nasogastric suction before sedation, reverse Trendelenburg position), and, when ap-

propriate, placement of an endotracheal tube for airway protection. Although the incidence of bacteremia with UGI dilation ranges from 12% to 22%, infectious sequelae are rare.<sup>47</sup> Therefore, antibiotic prophylaxis is not recommended.<sup>20</sup>

**Dilation of esophageal strictures.** The most common adverse events of esophageal dilation are perforation and bleeding. Wire-guided bougie dilation or through-the-scope balloon dilation may have lower risks of adverse events than blind passage of dilators.<sup>42</sup> Randomized trials suggest that wire-guided polyvinyl dilators and through-the-scope balloons have similar rates of both efficacy and adverse events.<sup>41,44,48,49</sup>

The rate of perforation after esophageal dilation for esophageal rings and simple peptic strictures is lower than that of certain high-risk lesions. Dilation of complex strictures (angulated, multiple, or long) with Maloney dilators may be associated with a 2% to 10% risk of perforation<sup>50,51</sup> so wire-guided or balloon dilation is likely a safer alternative.<sup>42</sup> Dilation of caustic strictures, which tend to be long and angulated, is associated with a higher rate of adverse events.<sup>52,53</sup> Dilation of eosinophilic esophagitis is associated with a high incidence of mucosal tears, but only 1 perforation was identified in a systematic review of 671 dilations for eosinophilic esophagitis.<sup>54</sup> The risk of perforation resulting from dilation of malignant strictures of the esophagus is approximately 10%<sup>55,56</sup> and is associated with increasing dilator diameter.<sup>56-59</sup> Radiation-induced strictures have also been reported to have a high rate of dilation-related adverse events,<sup>60</sup> but this risk may be related to the presence of malignancy rather than the effect of radiation.<sup>61</sup>

Pain is the most common symptom related to perforation.<sup>25,26,62,63</sup> Fever, crepitus, pleuritic chest pain, leukocytosis, and pleural effusion may also be present. Perforation with associated air dissection may be diagnosed by plain radiography of the neck and/or chest, but such findings may be absent immediately after perforation.<sup>64</sup> If a perforation is suspected, contrast esophagography should be performed, usually beginning with water-soluble contrast.<sup>65</sup> If the site of perforation cannot be determined but suspicion remains high, a barium esophagram or CT scan of the chest is indicated. A CT scan with oral contrast is sensitive for the site of perforation and for more subtle findings such as minute amounts of air or fluid.<sup>66</sup>

The approach to the patient with perforation depends on the state of health of the individual, the site of the perforation, and the overall prognosis. In selected patients, early recognition may allow nonoperative management with nasogastric suction, intravenous antibiotics, and parenteral nutrition.<sup>27</sup> Surgical consultation should be obtained, and surgical management is recommended for larger perforations in which the pleural space is involved or for failure to respond to medical management.<sup>28,29</sup> Case series of successful endoscopic closure of esophageal perforation with endoluminal stents, endoscopic clips, or su-

turing devices have been published,<sup>67-71</sup> although comparative data are lacking.

**Dilation for achalasia.** Pneumatic dilation of the lower esophageal sphincter is associated with increased risk of postprocedure pain, aspiration, bleeding, and perforation.<sup>72,73</sup> The rate of perforation is between 1.6% and 8%.<sup>73,74</sup> The risk of perforation may be lower when interval, graded dilation is used, beginning with a 30-mm diameter balloon and progressing to larger diameter balloons, only if symptoms do not improve. Using this technique, the overall risk of perforation is reported to be less than 2%.<sup>75-77</sup> Contrast esophagography should be performed for patients with persistent postprocedure pain, tachycardia, fever, or subcutaneous crepitus. Nonoperative management with nasogastric tube decompression and intravenous antibiotics may be used for contained perforations caused by pneumatic dilation.<sup>78</sup> Perforations resulting in extravasation of contrast during postprocedure esophagography may require operative intervention.<sup>77</sup>

**Dilation for benign gastric outlet obstruction.** Endoscopic balloon dilation for benign gastric outlet obstruction has been associated with perforation rates as high as 7.4%.<sup>79-84</sup> Risk factors for perforation include dilation in the setting of active ulceration<sup>83</sup> and dilation with balloons greater than 15 mm in diameter.<sup>80,82,83,85</sup> Graded dilation with stepwise increase of balloon size has been suggested to help reduce the risk of perforation.<sup>82,86</sup>

### Adverse events of foreign body retrieval

Adverse events attributable to endoscopic removal of foreign bodies are rare, and it can be difficult to determine whether the adverse event was caused by UGI endoscopy or the foreign object itself.<sup>87,88</sup> The most commonly reported adverse events are superficial mucosal laceration ( $\leq 2\%$ ), GI hemorrhage ( $\leq 1\%$ ), and perforation ( $\leq 0.8\%$ ).<sup>89-96</sup> Risk factors for perforation include removal of sharp, irregular objects, a delay of more than 24 to 48 hours to endoscopic intervention, and a history of repeated intentional foreign body ingestion.<sup>87,88,91,96-99</sup> Aspiration during endoscopic extraction of foreign bodies from the UGI tract is rarely reported<sup>91,96</sup> but deserves attention, especially when removing food piecemeal from the esophagus. The risk of aspiration may be minimized by using an esophageal overtube and/or endotracheal intubation. Injury during removal of sharp objects can be minimized by removing the object such that the sharp edge is trailing or by using an overtube.<sup>100</sup> After extraction of the foreign body, reinsertion of the endoscope should be performed to assess the mucosa for lacerations, bleeding, and the presence of underlying strictures or other pathology. Most mucosal injuries can be treated conservatively, and active bleeding that is not self-limited can be treated with standard endoscopic hemostasis techniques.<sup>100</sup> Further discussion of the management of foreign bodies can be found in a recent ASGE publication.<sup>101</sup>

### Adverse events of percutaneous endoscopic enteral access

The overall rate of adverse events with PEG placement is reported to be 4.9% to 10.3%.<sup>102</sup> Serious adverse events occur in 1.5% to 9.4% of PEG procedures and include aspiration, bleeding, injury to internal organs, perforation, "buried bumper syndrome," prolonged ileus, wound infection, necrotizing fasciitis, and death.<sup>102,103</sup> In a meta-analysis of 4194 PEG procedures, minor adverse events occurred in approximately 6% of patients and included tube occlusion, maceration from feeding tube leakage, and peristomal pain. PEG procedure-related mortality was reported to be 0.53% with a 30-day all-cause mortality rate of 14.7%.<sup>103</sup>

Peristomal wound infections are the most common infectious adverse events, occurring in 7% to 47% of patients receiving placebo in clinical trials. The pooled rate of wound infection in a meta-analysis of 10 randomized clinical trials was 26%.<sup>104</sup> A single dose of cephalosporin or penicillin-based prophylaxis resulted in a clinically significant reduction in PEG site wound infections,<sup>104</sup> and antibiotic prophylaxis for PEG placement is both cost-effective<sup>105</sup> and recommended for routine use.<sup>20</sup> Necrotizing fasciitis is a rare but serious adverse event with risk factors that include diabetes mellitus, atherosclerosis, alcoholism, malnutrition, immunosuppression, and older age.<sup>105-107</sup> Aspiration pneumonia may develop at the time of PEG placement, especially in those with oropharyngeal dysphagia.<sup>108,109</sup> Whether these patients aspirate during the procedure itself or aspirate their own secretions or tube-feeding material is difficult to ascertain. Pneumoperitoneum is typically a benign occurrence, which has been reported in 12% to 38% of patients undergoing uncomplicated PEG.<sup>110-112</sup>

Bleeding from gastric or abdominal wall vessels is reported in less than 1% of procedures.<sup>108,113</sup> Anticoagulants should be held or reversed before PEG placement.<sup>31</sup> Injury to internal organs such as the liver, small bowel, and colon can occur during needle insertion.<sup>114-118</sup> Gastric tears are a rare occurrence during PEG placement.<sup>108,119</sup> Prevention of such injuries may be best achieved by ensuring adequate transillumination and finger indentation when placing the PEG and by use of the "safe-tract" technique.<sup>120,121</sup> The optimal management of gastric laceration, peritonitis, or colonic perforation is poorly studied, although surgical exploration will likely be required.<sup>115</sup> An asymptomatic or chronic cologastrocutaneous fistula may be treated with simple removal of the tube, and the fistula is reported to heal within hours.<sup>122</sup> Feeding tubes may become impacted in the abdominal wall.<sup>123,124</sup> The "buried bumper syndrome" is believed to result from excessive traction on the internal PEG bolster, causing ischemic necrosis of the gastric wall. Endoscopically, the PEG may not be visible. Treatment involves removal of the tube and placement of a new tube.<sup>125</sup>

Metastasis developing at the PEG insertion site in patients with head and neck cancers has been reported.<sup>126</sup> It is unclear whether this results from hematogenous spread or transport of exfoliated tumor cells during passage of the feeding tube past the tumor. If PEG-site metastasis is a concern for any particular patient, other techniques may be reasonable alternatives to a PEG.<sup>127</sup>

Accidental early tube removal may result in peritonitis if a mature fistulous tract has not developed. If a mature tract is present (>1 month), then a suitable replacement tube should be inserted as soon as possible. Contrast injection and fluoroscopy can be used to confirm correct tube location when there is uncertainty as to the maturity of the tract.<sup>128,129</sup>

Adverse events associated with percutaneous endoscopic jejunostomy are similar to those of standard PEG placement, although the rate is higher.<sup>129-134</sup> Adverse events unique to PEG with jejunal extension are typically caused by the small-diameter jejunal feeding extension and include clogging (4%-18%), unintentional removal (11%-18%), and tube migration (6%).<sup>129,130,134,135</sup>

## Adverse events of endoluminal therapy

**Resection techniques.** Endoscopic polypectomy in the UGI tract is associated with low rates of pain, bleeding, and perforation.<sup>136</sup> Immediate bleeding after gastric polypectomy is more common than bleeding after polypectomy at other sites, with rates ranging from 3.4% to 7.2%.<sup>136-139</sup> Delayed bleeding after polypectomy of duodenal adenomas is reported in 3.1% to 22% of patients.<sup>140-142</sup>

EMR is used to excise focal lesions of the mucosa and involves resection into the submucosal layer. Common self-limited adverse events of EMR include chest pain, abdominal pain, dysphagia, odynophagia, and dyspepsia.<sup>143</sup> The overall incidence of serious adverse events such as bleeding, perforation, and stricture has been estimated to be between 0.5% and 5%.<sup>144</sup> Bleeding occurs more often with multifocal EMR and with EMR of gastric lesions.<sup>143-145</sup> Perforation with gastric EMR is reported more frequently than with esophageal EMR, possibly because of the larger lesions encountered in the stomach.<sup>146</sup> Stricture formation is mostly reported after esophageal EMR, especially when circumferential resection is performed. The incidence of esophageal stricture after focal EMR is less than 0.5%, compared with an incidence of 12% to 35% when more than 50% of the esophageal circumference is resected.<sup>145,147</sup>

Endoscopic submucosal dissection (ESD) allows for en bloc excision of large mucosal lesions of the GI tract by using a variety of specialized accessories.<sup>148,149</sup> Adverse events of ESD are similar to those of EMR, but occur with greater frequency given the larger areas of resection. The overall incidence of bleeding and perforation with ESD is 11% and 6%, respectively.<sup>143-146,148</sup> Asymptomatic pneu-

momediastinum may occur in as many as 31% of ESDs and is of uncertain clinical significance.<sup>150</sup>

**Ablation techniques.** Ablation of mucosal lesions of the UGI tract can be performed with a variety of devices including heater probes, multipolar electrocoagulation, argon plasma coagulation (APC), and Nd-YAG laser. Self-limited adverse events commonly reported include pain, dysphagia, and nausea. The incidence of serious adverse events associated with APC appears to be higher than that of other modalities, especially when treating long segments of Barrett's esophagus or with multiple sessions of ablation.<sup>151-154</sup> Randomized trials with APC report bleeding rates of as high as 4%, esophageal perforation in as many as 2% of patients, and stricture formation in as many as 6% of patients.<sup>151,155,156</sup>

Photodynamic therapy (PDT) with porfimer sodium as a photosensitizing agent is used for palliation of dysphagia in advanced esophageal cancer and for ablation of Barrett's epithelium with high-grade dysplasia. PDT of the esophagus frequently causes chest pain, fever, and pleural effusion.<sup>157,158</sup> PDT with porfimer sodium results in esophageal stricture formation in 11% to 42% of patients.<sup>155,159</sup> Photosensitivity reactions occur in 10% to 60% of patients.<sup>157,160</sup>

Radiofrequency ablation (RFA) of Barrett's epithelium has a relatively favorable adverse event profile. In 1 randomized trial, the degree of chest discomfort was higher after RFA than in the control group, but resolved within 8 days of the procedure.<sup>161</sup> Superficial lacerations have been noted during 6% of procedures,<sup>162</sup> but bleeding requiring endoscopic therapy occurred in less than 2% of procedures.<sup>161-164</sup> The incidence of RFA-associated esophageal stricture ranges from 2% to 8%.<sup>161-163</sup> Procedure-related perforation has been reported.<sup>165</sup>

Cryotherapy has not been as well studied to date. Small case series report common self-limited symptoms such as pain and dysphagia. The incidence of strictures ranges between 4% and 10%.<sup>166-168</sup> Esophageal perforation was reported in 1 patient with Marfan syndrome undergoing liquid nitrogen cryotherapy.<sup>167</sup>

**Endoscopic stents.** Stents may be deployed endoscopically to achieve luminal patency in any part of the UGI tract. Rigid esophageal stents are no longer used and have been replaced by self-expanding stents.<sup>169,170</sup> Immediate adverse events of esophageal self-expandable metal stents (SEMSs) occur in 2% to 12% of patients and include aspiration, respiratory compromise caused by tracheal compression, improper positioning, and perforation.<sup>170-173</sup> Immediate adverse events may be minimized by adequate patient preparation and positioning, familiarity of the endoscopist with the stent mechanism and characteristics, the use of soft-tipped guidewires, and avoidance of aggressive pre-stent dilation.<sup>174,175</sup> Early postdeployment adverse events, such as chest pain and nausea, are common and resolve with conservative measures in most cases.<sup>170,176,177</sup> Significant bleeding after SEMS placement

is not common, but may be life-threatening.<sup>178</sup> Late adverse events after esophageal SEMS placement occur in 20% to 40%.<sup>179</sup> Pyrosis and regurgitation are common when the gastroesophageal junction is bridged with a stent. Strict antireflux measures, high-dose acid suppression, and the use of stents designed to prevent reflux have been used with varying degrees of success.<sup>180-182</sup> Recurrent occlusion of SEMS is reported in as many as 30% of patients and can occur because of tumor overgrowth, tissue hyperplasia at the ends of the stent, stent migration, or food impaction.<sup>173</sup> The use of covered stents reduces the risk of tumor ingrowth.<sup>173,177</sup> Occlusion by tissue may be treated by endoscopic ablation of the tissue or placement of a second stent.<sup>183</sup> Food impactions may be managed endoscopically.<sup>184</sup> Late perforation of the esophagus caused by ischemia of the esophageal wall and tracheoesophageal fistulae have been reported.<sup>178,183,184</sup> Pretreatment with chemoradiotherapy has been reported to increase the incidence of adverse events of esophageal SEMSs by some authors<sup>185</sup> but not by others.<sup>186,187</sup>

Gastroduodenal stents are associated with similar adverse events as esophageal SEMS. Severe early adverse events, such as bleeding and perforation, are reported in 1% to 5% of patients.<sup>188-190</sup> Aspiration is a significant concern during initial placement, and precautions for airway protection should be taken.<sup>175</sup> Stent migration, early malfunction or occlusion, and late stent occlusion are common adverse events of gastroduodenal stents.<sup>191</sup> The rate of reintervention for SEMS placed in patients with malignant gastroduodenal obstruction is 20% to 30%.<sup>188,191-193</sup>

## Endoscopic variceal hemostasis

**Endoscopic variceal sclerotherapy (EVS).** The sclerosants used for EVS include sodium tetradecyl sulfate, sodium morrhuate, ethanolamine oleate, absolute alcohol, and cyanoacrylate. No single sclerosant has demonstrated superiority over the others. The overall adverse event rate from EVS has been estimated to be between 35% and 78%, with a mortality rate of 1% to 5%.<sup>194,195</sup>

Ulcerations caused by EVS occur in 50% to 78% of patients<sup>196,197</sup> but may be more common if treatments are conducted in closely timed (<1 week) sessions.<sup>198,199</sup> H<sub>2</sub> receptor antagonists, proton pump inhibitors, and sucralfate do not prevent ulcer formation,<sup>200-202</sup> but omeprazole may be effective in healing these ulcerations.<sup>203,204</sup> Significant immediate bleeding occurs in 6% of patients<sup>196</sup> and can often be controlled by local endoscopic techniques.<sup>205</sup> Significant delayed bleeding in 19% to 24% of patients can be caused by recurrent variceal bleeding,<sup>206,207</sup> ulceration, or esophagitis.<sup>205</sup> Intramural hematoma has been reported in as many as 1.6% of patients and usually resolves spontaneously.<sup>208</sup>

Esophageal stricture formation occurs in as many as 20% of patients.<sup>209,210</sup> The rate of stricture formation may correlate with the number of EVS sessions and the amount of sclerosant used.<sup>211</sup> Esophageal perforation

occurs in 0.5% to 5% of patients after EVS.<sup>208,212,213</sup> Conservative management of localized perforations has been reported,<sup>214</sup> but free perforations carry a poor prognosis in this patient group.<sup>213,215</sup> Aspiration pneumonia has been reported in as many as 5% of patients after EVS and usually occurs during emergent sessions for variceal bleeding.<sup>210,211,216</sup>

EVS may cause extension of thrombus into the portal and mesenteric venous systems, resulting in mesenteric or splenic infarction.<sup>217,218</sup> Cyanoacrylate injection in particular has been reported to cause systemic emboli to the lung, spleen, and portal vein.<sup>219,220</sup>

Bacterial infections occur in as many as 50% of cirrhotic patients admitted with GI hemorrhage of any etiology.<sup>221</sup> EVS may further increase the risk of bacteremia in actively bleeding patients.<sup>222,223</sup> Prophylactic antibiotics are recommended for actively bleeding cirrhotic patients, but not for elective variceal sclerotherapy.<sup>20,221</sup>

**Endoscopic band ligation (EBL).** Endoscopic band ligation is associated with lower rates of adverse events and mortality than EVS.<sup>194,224</sup> Esophageal ulcer formation with EBL is reported in 5% to 15% of patients,<sup>210,216,224,225</sup> Proton pump inhibitors have been shown to facilitate healing of EBL ulcers.<sup>226</sup> Perforation is extremely rare and is usually associated with use of an overtube to assist multiple endoscope passes.<sup>210,216,224</sup> Overtube use for EBL is discouraged. Esophageal stricture formation as a consequence of EBL is rare. No strictures were reported in multiple randomized trials,<sup>210,216,224,225</sup> but a few cases have been reported.<sup>227</sup> Aspiration pneumonia and bacterial peritonitis after EBL have been reported in approximately 1% and 4% of patients, respectively.<sup>210,216,224,225</sup>

## Endoscopic nonvariceal hemostasis

The overall incidence of major adverse events associated with endoscopic nonvariceal hemostasis (ie, perforation and exacerbation of bleeding) is less than 0.5%.<sup>228-230</sup> Injection hemostasis with cyanoacrylate, polidocanol, ethanol, or thrombin has been rarely reported to cause focal tissue necrosis, perforation,<sup>231,232</sup> or exacerbation of bleeding.<sup>233</sup> Randomized, controlled trials using multipolar electrocautery or heater probe have reported rates of perforation as high as 2%.<sup>234-237</sup> The rate of perforation may be higher ( $\leq 4\%$ ) with repeat heater probe treatment when performed within 24 to 48 hours of the initial session.<sup>238</sup> Induction or exacerbation of bleeding is a relatively common adverse event of thermal hemostasis, occurring in as many as 5% of cases.<sup>229,235,236,239</sup> Although dual therapy with both epinephrine and a thermal modality or with 2 types of injectates is as effective as monotherapy with either a thermal technique or endoscopic clips, adverse events may be higher with dual therapy.<sup>229,235</sup>

Endoscopic clips are the most commonly used mechanical device for endoscopic hemostasis. There have been no significant procedure-related adverse events associated with the use of endoscopic clips in clinical trials.<sup>229,237,240</sup>

## ENDOSCOPIC MANAGEMENT OF ADVERSE EVENTS OF ENDOLUMINAL THERAPY

Many of the adverse events associated with endoluminal therapy can be treated endoscopically. Bleeding can be controlled with injection hemostasis, APC, hemostatic graspers, or endoscopic clips.<sup>147,148,241</sup> The risk of delayed bleeding after EMR may be reduced by prophylactic closure of mucosal defects with endoscopic clips.<sup>142,242</sup> High-dose proton pump inhibitor therapy improves ulcer healing rates and reduces the risk of delayed bleeding after ESD.<sup>148</sup>

Perforation caused by EMR or ESD may be managed by application of endoscopic clips and conservative measures, if identified during the initial procedure.<sup>143,243</sup> Perforations through a neoplasm or at a site of significant inflammation may not be amenable to endoscopic clip closure and may require surgical attention. Rare cases of delayed perforation requiring surgical management have been reported after ESD.<sup>148</sup> EMR of ulcerated lesions or lesions that do not lift adequately with submucosal injection may have a higher risk of perforation.<sup>244</sup> Strictures resulting from endoluminal therapy can be treated with bougies or balloon dilators<sup>147,148,156,158,161</sup> but may require multiple frequent sessions for complete resolution of symptoms.

## ADVERSE EVENTS OF SMALL-BOWEL ENTEROSCOPY

Deep enteroscopy using techniques such as double-balloon enteroscopy (DBE), single-balloon enteroscopy, or spiral enteroscopy have the potential for unique adverse events. Most data stem from DBE studies. A recent meta-analysis found major adverse events in 0.7% of 9047 DBE procedures, including perforation (n = 20), pancreatitis (n = 17), aspiration pneumonia (n = 8), bleeding (n = 6), and 1 death.<sup>245</sup> Minor adverse events were reported in 9.1% of 2017 procedures. The adverse event rate is higher for therapeutic DBE (4.3%) than for diagnostic DBE (0.8%),<sup>246</sup> and perforation is more likely to occur in patients with altered surgical anatomy.<sup>247</sup> The rate of bleeding or perforation may be as high as 10.8% for patients undergoing polypectomy during DBE.<sup>245</sup> Self-limited abdominal pain has been reported in as many as 20% of patients.<sup>248</sup> Pancreatitis is a relatively unique adverse event of balloon enteroscopy, occurring in 0.49%.<sup>245</sup> The pathogenesis of acute pancreatitis caused by DBE has not been determined, but it may be a result of direct trauma to the pancreas or balloon insufflation in the region of the ampulla.

## CONCLUSIONS

Adverse events are inherent in the performance of UGI endoscopic procedures. Because endoscopy assumes a more therapeutic role in the management of GI disorders, the potential for adverse events will likely increase.

Knowledge of potential endoscopic adverse events, their expected frequency, and the risk factors for their occurrence may help to minimize the incidence of adverse events. Endoscopists are expected to carefully select patients for the appropriate intervention, be familiar with the planned procedure and available technology, and be prepared to manage any adverse events that may arise. Once an adverse event occurs, early recognition and prompt intervention may minimize the morbidity and mortality associated with that adverse event. Review of adverse events as part of a continuing quality improvement process may serve to educate endoscopists, help to reduce the risk of future adverse events, and improve the overall quality of endoscopy.<sup>249</sup>

## DISCLOSURE

*All authors disclosed no financial relationships relevant to this publication.*

*Abbreviations: APC, argon plasma coagulation; ASGE, American Society for Gastrointestinal Endoscopy; DBE, double-balloon enteroscopy; EBL, endoscopic band ligation; ESD, endoscopic submucosal dissection; EVS, endoscopic variceal sclerotherapy; PDT, photodynamic therapy; RFA, radiofrequency ablation; SEMS, self-expandable metal stents; UGI, upper GI.*

## REFERENCES

- Silvis SE, Nebel O, Rogers G, et al. Endoscopic complications. Results of the 1974 American Society for Gastrointestinal Endoscopy Survey. *JAMA* 1976;235:928-30.
- Froehlich F, Gonvers JJ, Fried M. Conscious sedation, clinically relevant complications and monitoring of endoscopy: results of a nationwide survey in Switzerland. *Endoscopy* 1994;26:231-4.
- Quine MA, Bell GD, McCloy RF, et al. Prospective audit of upper gastrointestinal endoscopy in two regions of England: safety, staffing, and sedation methods. *Gut* 1995;36:462-7.
- Sieg A, Hachmoeller-Eisenbach U, et al. Prospective evaluation of complications in outpatient GI endoscopy: a survey among German gastroenterologists. *Gastrointest Endosc* 2001;53:620-7.
- Wolfsen HC, Hemminger LL, Achem SR, et al. Complications of endoscopy of the upper gastrointestinal tract: a single-center experience. *Mayo Clin Proc* 2004;79:1264-7.
- Heuss LT, Froehlich F, Beglinger C. Changing patterns of sedation and monitoring practice during endoscopy: results of a nationwide survey in Switzerland. *Endoscopy* 2005;37:161-6.
- Sharma VK, Nguyen CC, Crowell MD, et al. A national study of cardiopulmonary unplanned events after GI endoscopy. *Gastrointest Endosc* 2007;66:27-34.
- Cotton PB, Eisen GM, Aabakken L, et al. A lexicon for endoscopic adverse events: report of an ASGE workshop. *Gastrointest Endosc* 2010;71:446-54.
- Zubarik R, Eisen G, Mastropietro C, et al. Prospective analysis of complications 30 days after outpatient upper endoscopy. *Am J Gastroenterol* 1999;94:1539-45.
- Mallery JS, Baron TH, Dominitz JA, et al. Complications of ERCP. *Gastrointest Endosc* 2003;57:633-8.
- Adler DG, Jacobson BC, Davila RE, et al. ASGE guideline: complications of EUS. *Gastrointest Endosc* 2005;61:8-12.
- Cohen LB, Wechsler JS, Gaetano JN, et al. Endoscopic sedation in the United States: results from a nationwide survey. *Am J Gastroenterol* 2006;101:967-74.

13. Gangi S, Saidi F, Patel K, et al. Cardiovascular complications after GI endoscopy: occurrence and risks in a large hospital system. *Gastrointest Endosc* 2004;60:679-85.
14. Clarke GA, Jacobson BC, Hammett RJ, et al. The indications, utilization and safety of gastrointestinal endoscopy in an extremely elderly patient cohort. *Endoscopy* 2001;33:580-4.
15. Bell GD, Bown S, Morden A, et al. Prevention of hypoxaemia during upper-gastrointestinal endoscopy by means of oxygen via nasal cannulae. *Lancet* 1987;1:1022-4.
16. Griffin SM, Chung SC, Leung JW, et al. Effect of intranasal oxygen on hypoxia and tachycardia during endoscopic cholangiopancreatography. *BMJ* 1990;300:83-4.
17. Lichtenstein DR, Jagannath S, Baron TH, et al. Sedation and anesthesia in GI endoscopy. *Gastrointest Endosc* 2008;68:815-26.
18. American Society of Anesthesiologists Task Force on Sedation and Analgesia by Non-Anesthesiologists. Practice guidelines for sedation and analgesia by non-anesthesiologists. *Anesthesiology* 2002;96:1004-17.
19. American Society for Gastrointestinal Endoscopy. Multi-society guideline for reprocessing flexible gastrointestinal endoscopes. *Gastrointest Endosc* 2003;58:1-8.
20. Banerjee S, Shen B, Baron TH, et al. Antibiotic prophylaxis for GI endoscopy. *Gastrointest Endosc* 2008;67:791-8.
21. Nelson DB. Infectious disease complications of GI endoscopy: Part I, endogenous infections. *Gastrointest Endosc* 2003;57:546-56.
22. Allison MC, Sandoe JA, Tighe R, et al. Antibiotic prophylaxis in gastrointestinal endoscopy. *Gut* 2009;58:869-80.
23. Wilson W, Taubert KA, Gewitz M, et al. Prevention of infective endocarditis: guidelines from the American Heart Association: a guideline from the American Heart Association Rheumatic Fever, Endocarditis, and Kawasaki Disease Committee, Council on Cardiovascular Disease in the Young, and the Council on Clinical Cardiology, Council on Cardiovascular Surgery and Anesthesia, and the Quality of Care and Outcomes Research Interdisciplinary Working Group. *Circulation* 2007;116:1736-54.
24. Quine MA, Bell GD, McCloy RF, et al. Prospective audit of perforation rates following upper gastrointestinal endoscopy in two regions of England. *Br J Surg* 1995;82:530-3.
25. Schulze S, Möller Pedersen V, Hóier-Madsen K. Iatrogenic perforation of the esophagus. Causes and management. *Acta Chir Scand* 1982;148:679-82.
26. Pettersson G, Larsson S, Gatzinsky P, et al. Differentiated treatment of intrathoracic oesophageal perforations. *Scand J Thorac Cardiovasc Surg* 1981;15:321-4.
27. Vogel SB, Rout WR, Martin TD, et al. Esophageal perforation in adults: aggressive, conservative treatment lowers morbidity and mortality. *Ann Surg* 2005;241:1016-21; discussion 1021-3.
28. Eroglu A, Turkyilmaz A, Aydin Y, et al. Current management of esophageal perforation: 20 years experience. *Dis Esophagus* 2009;22:374-80.
29. Abbas G, Schuchert MJ, Pettiford BL, et al. Contemporaneous management of esophageal perforation. *Surgery* 2009;146:749-55.
30. Lai CH, Lau WY. Management of endoscopic retrograde cholangiopancreatography-related perforation. *Surgeon* 2008;6:45-8.
31. Anderson MA, Ben-Menachem T, Gan SI, et al. Management of antithrombotic agents for endoscopic procedures. *Gastrointest Endosc* 2009;70:1060-70.
32. Montalvo RD, Lee M. Retrospective analysis of iatrogenic Mallory-Weiss tears occurring during upper gastrointestinal endoscopy. *Hepato-gastroenterology* 1996;43:174-7.
33. Chu DZ, Shivshanker K, Stroehlein JR, et al. Thrombocytopenia and gastrointestinal hemorrhage in the cancer patient: prevalence of unmasked lesions. *Gastrointest Endosc* 1983;29:269-72.
34. Vishny ML, Blades EW, Creger RJ, et al. Role of upper endoscopy in evaluation of upper gastrointestinal symptoms in patients undergoing bone marrow transplantation. *Cancer Invest* 1994;12:384-9.
35. Chongsrisawat V, Suprajitporn V, Kittikalayawong Y, et al. Platelet count in predicting bleeding complication after elective endoscopy in children with portal hypertension and thrombocytopenia. *Asian Biomed* 2009;3:731-4.
36. Khan K, Schwarzenberg SJ, Sharp H, et al. Diagnostic endoscopy in children after hematopoietic stem cell transplantation. *Gastrointest Endosc* 2006;64:379-85.
37. Van Os EC, Kamath PS, Gostout CJ, et al. Gastroenterological procedures among patients with disorders of hemostasis: evaluation and management recommendations. *Gastrointest Endosc* 1999;50:536-43.
38. Rebullia P. Revisitation of the clinical indications for the transfusion of platelet concentrates. *Rev Clin Exp Hematol* 2001;5:288-310.
39. Samama CM, Djoudi R, Lecompte T, et al. Perioperative platelet transfusion: recommendations of the Agence Francaise de Securite Sanitaire des Produits de Sante (AFSSaPS) 2003. *Can J Anaesth* 2005;52:30-7.
40. British Society of Gastroenterology. Guidelines on complications of gastrointestinal endoscopy. 2006. Available at: <http://www.bsg.org.uk/clinical-guidelines>. Accessed May 15, 2011.
41. Cox JG, Winter RK, Maslin SC, et al. Balloon or bougie for dilatation of benign esophageal stricture? *Dig Dis Sci* 1994;39:776-81.
42. Hernandez LV, Jacobson JW, Harris MS. Comparison among the perforation rates of Maloney, balloon, and Savary dilation of esophageal strictures. *Gastrointest Endosc* 2000;51:460-2.
43. Lew RJ, Kochman ML. A review of endoscopic methods of esophageal dilation. *J Clin Gastroenterol* 2002;35:117-26.
44. Scolapio JS, Pasha TM, Gostout CJ, et al. A randomized prospective study comparing rigid to balloon dilators for benign esophageal strictures and rings. *Gastrointest Endosc* 1999;50:13-7.
45. Lehmann KG, Blair DN, Siskind BN, et al. Right atrial-esophageal fistula and hydropneumopericardium after esophageal dilation. *J Am Coll Cardiol* 1987;9:969-72.
46. Pioret E, Escher A, Monnier P. Esophageal and pharyngeal strictures: report on 1,862 endoscopic dilations using the Savary-Gilliard technique. *Eur Arch Otorhinolaryngol* 2008;265:357-64.
47. Nelson DB, Sanderson SJ, Azar MM. Bacteremia with esophageal dilation. *Gastrointest Endosc* 1998;48:563-7.
48. Saeed ZA, Winchester CB, Ferro PS, et al. Prospective randomized comparison of polyvinyl bougies and through-the-scope balloons for dilation of peptic strictures of the esophagus. *Gastrointest Endosc* 1995;41:189-95.
49. Shemesh E, Czerniak A. Comparison between Savary-Gilliard and balloon dilatation of benign esophageal strictures. *World J Surg* 1990;14:518-21.
50. Patterson DJ, Graham DY, Smith JL, et al. Natural history of benign esophageal stricture treated by dilatation. *Gastroenterology* 1983;85:346-50.
51. McClave SA, Brady PG, Wright RA, et al. Does fluoroscopic guidance for Maloney esophageal dilation impact on the clinical endpoint of therapy: relief of dysphagia and achievement of luminal patency. *Gastrointest Endosc* 1996;43:93-7.
52. Broor SL, Lahoti D, Bose PP, et al. Benign esophageal strictures in children and adolescents: etiology, clinical profile, and results of endoscopic dilation. *Gastrointest Endosc* 1996;43:474-7.
53. Karnak I, Tanyel FC, Buyukpamukcu N, et al. Esophageal perforations encountered during the dilation of caustic esophageal strictures. *J Cardiovasc Surg* 1998;39:373-7.
54. Jacobs JW Jr, Spechler SJ. A systematic review of the risk of perforation during esophageal dilation for patients with eosinophilic esophagitis. *Dig Dis Sci* 2010;55:1512-5.
55. Anderson PE, Cook A, Amery AH. A review of the practice of fiberoptic endoscopic dilatation of oesophageal stricture. *Ann R Coll Surg Engl* 1989;71:124-7.
56. Van Dam J, Rice TW, Catalano MF, et al. High-grade malignant stricture is predictive of esophageal tumor stage. Risks of endosonographic evaluation. *Cancer* 1993;71:2910-7.
57. Catalano MF, Van Dam J, Sivak MV Jr. Malignant esophageal strictures: staging accuracy of endoscopic ultrasonography. *Gastrointest Endosc* 1995;41:535-9.

58. Pfau PR, Ginsberg GG, Lew RJ, et al. Esophageal dilation for endosonographic evaluation of malignant esophageal strictures is safe and effective. *Am J Gastroenterol* 2000;95:2813-5.
59. Wallace MB, Hawes RH, Sahai AV, et al. Dilation of malignant esophageal stenosis to allow EUS guided fine-needle aspiration: safety and effect on patient management. *Gastrointest Endosc* 2000;51:309-13.
60. Swaroop VS, Desai DC, Mohandas KM, et al. Dilation of esophageal strictures induced by radiation therapy for cancer of the esophagus. *Gastrointest Endosc* 1994;40:311-5.
61. Ng TM, Spencer GM, Sargeant IR, et al. Management of strictures after radiotherapy for esophageal cancer. *Gastrointest Endosc* 1996;43:584-90.
62. Larsen K, Skov Jensen B, Axelsen F. Perforation and rupture of the esophagus. *Scand J Thorac Cardiovasc Surg* 1983;17:311-6.
63. Wychulis AR, Fontana RS, Payne WS. Instrumental perforations of the esophagus. *Dis Chest* 1969;55:184-9.
64. Panzini L, Burrell MI, Traube M. Instrumental esophageal perforation: chest film findings. *Am J Gastroenterol* 1994;89:367-70.
65. Gimenez A, Franquet T, Erasmus JJ, et al. Thoracic complications of esophageal disorders. *Radiographics* 2002;22(Spec no):S247-58.
66. Wu JT, Mattox KL, Wall MJ Jr. Esophageal perforations: new perspectives and treatment paradigms. *J Trauma* 2007;63:1173-84.
67. Bresadola V, Terrosu G, Favero A, et al. Treatment of perforation in the healthy esophagus: analysis of 12 cases. *Langenbecks Arch Surg* 2008;393:135-40.
68. Qadeer MA, Dumot JA, Vargo JJ, et al. Endoscopic clips for closing esophageal perforations: case report and pooled analysis. *Gastrointest Endosc* 2007;66:605-11.
69. Raju GS. Endoscopic closure of gastrointestinal leaks. *Am J Gastroenterol* 2009;104:1315-20.
70. Tuebergen D, Rijcken E, Mennigen R, et al. Treatment of thoracic esophageal anastomotic leaks and esophageal perforations with endoluminal stents: efficacy and current limitations. *J Gastrointest Surg* 2008;12:1168-76.
71. van Heel NCM, Haringsma J, Spaander MCW, et al. Short-term esophageal stenting in the management of benign perforations. *Am J Gastroenterol* 2010;105:1515-20.
72. Eckardt VF, Kanzler G, Westemeier T. Complications and their impact after pneumatic dilation for achalasia: prospective long-term follow-up study. *Gastrointest Endosc* 1997;45:349-53.
73. Nair LA, Reynolds JC, Parkman HP, et al. Complications during pneumatic dilation for achalasia or diffuse esophageal spasm. Analysis of risk factors, early clinical characteristics, and outcome. *Dig Dis Sci* 1993;38:1893-904.
74. Campos GM, Vittinghoff E, Rabl C, et al. Endoscopic and surgical treatments for achalasia: a systematic review and meta-analysis. *Ann Surg* 2009;249:45-57.
75. Boeckxstaens GE, Annese V, des Varannes SB, et al. The European Achalasia Trial: a randomized multi-centre trial comparing endoscopic pneumodilation and laparoscopic myotomy as primary treatment of idiopathic achalasia. *Gastroenterology* 2010;138:S-53.
76. Kadakia SC, Wong RK. Graded pneumatic dilation using Rigiflex achalasia dilators in patients with primary esophageal achalasia. *Am J Gastroenterol* 1993;88:34-8.
77. Mikaeli J, Bishehsari F, Montazeri G, et al. Pneumatic balloon dilatation in achalasia: a prospective comparison of safety and efficacy with different balloon diameters. *Aliment Pharmacol Ther* 2004;20:431-6.
78. Molina EG, Stollman N, Grauer L, et al. Conservative management of esophageal nontransmural tears after pneumatic dilation for achalasia. *Am J Gastroenterol* 1996;91:15-8.
79. Cherian PT, Cherian S, Singh P. Long-term follow-up of patients with gastric outlet obstruction related to peptic ulcer disease treated with endoscopic balloon dilatation and drug therapy. *Gastrointest Endosc* 2007;66:491-7.
80. DiSario JA, Fennerty MB, Tietze CC, et al. Endoscopic balloon dilation for ulcer-induced gastric outlet obstruction. *Am J Gastroenterol* 1994;89:868-71.
81. Hewitt PM, Krige JE, Funnell IC, et al. Endoscopic balloon dilatation of peptic pyloroduodenal strictures. *J Clin Gastroenterol* 1999;28:33-5.
82. Lam YH, Lau JY, Fung TM, et al. Endoscopic balloon dilation for benign gastric outlet obstruction with or without *Helicobacter pylori* infection. *Gastrointest Endosc* 2004;60:229-33.
83. Lau JY, Chung SC, Sung JJ, et al. Through-the-scope balloon dilation for pyloric stenosis: long-term results. *Gastrointest Endosc* 1996;43:98-101.
84. Solt J, Bajor J, Szabo M, et al. Long-term results of balloon catheter dilation for benign gastric outlet stenosis. *Endoscopy* 2003;35:490-5.
85. Fukami N, Anderson MA, Khan K, et al. The role of endoscopy in gastroduodenal obstruction and gastroparesis. *Gastrointest Endosc* 2011;74:13-21.
86. Banerjee S, Cash BD, Dominitz JA, et al. The role of endoscopy in the management of patients with peptic ulcer disease. *Gastrointest Endosc* 2010;71:663-8.
87. Gregori D, Scarinzi C, Morra B, et al. Ingested foreign bodies causing complications and requiring hospitalization in European children: results from the ESFBI study. *Pediatr Int* 2010;52:26-32.
88. Palta R, Sahota A, Bemarki A, et al. Foreign-body ingestion: characteristics and outcomes in a lower socioeconomic population with predominantly intentional ingestion. *Gastrointest Endosc* 2009;69:426-33.
89. Arms JL, Mackenberg-Mohn MD, Bowen MV, et al. Safety and efficacy of a protocol using bougienage or endoscopy for the management of coins acutely lodged in the esophagus: a large case series. *Ann Emerg Med* 2008;51:367-72.
90. Cheng W, Tam PK. Foreign-body ingestion in children: experience with 1,265 cases. *J Pediatr Surg* 1999;34:1472-6.
91. Li ZS, Sun ZX, Zou DW, et al. Endoscopic management of foreign bodies in the upper-GI tract: experience with 1088 cases in China. *Gastrointest Endosc* 2006;64:485-92.
92. Lin HH, Lee SC, Chu HC, et al. Emergency endoscopic management of dietary foreign bodies in the esophagus. *Am J Emerg Med* 2007;25:662-5.
93. Longstreth GF, Longstreth KJ, Yao JF. Esophageal food impaction: epidemiology and therapy. A retrospective, observational study. *Gastrointest Endosc* 2001;53:193-8.
94. Mosca S, Manes G, Martino R, et al. Endoscopic management of foreign bodies in the upper gastrointestinal tract: report on a series of 414 adult patients. *Endoscopy* 2001;33:692-6.
95. Vicari JJ, Johanson JF, Frakes JT. Outcomes of acute esophageal food impaction: success of the push technique. *Gastrointest Endosc* 2001;53:178-81.
96. Zhang S, Cui Y, Gong X, et al. Endoscopic management of foreign bodies in the upper gastrointestinal tract in South China: a retrospective study of 561 cases. *Dig Dis Sci* 2010;55:1305-12.
97. Gracia C, Frey CF, Bodai BI. Diagnosis and management of ingested foreign bodies: a ten-year experience. *Ann Emerg Med* 1984;13:30-4.
98. Katsinelos P, Kountouras J, Paroutoglou G, et al. Endoscopic techniques and management of foreign body ingestion and food bolus impaction in the upper gastrointestinal tract: a retrospective analysis of 139 cases. *J Clin Gastroenterol* 2006;40:784-9.
99. Webb WA. Management of foreign bodies of the upper gastrointestinal tract: update. *Gastrointest Endosc* 1995;41:39-51.
100. Ginsberg GG. Management of ingested foreign objects and food bolus impactions. *Gastrointest Endosc* 1995;41:33-8.
101. Ikenberry SO, Jue TL, Anderson MA, et al. Management of ingested foreign bodies and food impactions. *Gastrointest Endosc* 2011;73:1085-91.
102. McClave SA, Chang WK. Complications of enteral access. *Gastrointest Endosc* 2003;58:739-51.
103. Wollman B, D'Agostino HB, Walus-Wigle JR, et al. Radiologic, endoscopic, and surgical gastrostomy: an institutional evaluation and meta-analysis of the literature. *Radiology* 1995;197:699-704.



104. Jafri NS, Mahid SS, Minor KS, et al. Meta-analysis: antibiotic prophylaxis to prevent peristomal infection following percutaneous endoscopic gastrostomy. *Aliment Pharmacol Ther* 2007;25:647-56.
105. Kulling D, Sonnenberg A, Fried M, et al. Cost analysis of antibiotic prophylaxis for PEG. *Gastrointest Endosc* 2000;51:152-6.
106. Cave DR, Robinson WR, Brotschi EA. Necrotizing fasciitis following percutaneous endoscopic gastrostomy. *Gastrointest Endosc* 1986;32:294-6.
107. Haas DW, Dharmaraja P, Morrison JG, et al. Necrotizing fasciitis following percutaneous endoscopic gastrostomy. *Gastrointest Endosc* 1988;34:487-8.
108. Jain NK, Larson DE, Schroeder KW, et al. Antibiotic prophylaxis for percutaneous endoscopic gastrostomy. A prospective, randomized, double-blind clinical trial. *Ann Intern Med* 1987;107:824-8.
109. Shastri YM, Shirodkar M, Mallath MK. Endoscopic feeding tube placement in patients with cancer: a prospective clinical audit of 2055 procedures in 1866 patients. *Aliment Pharmacol Ther* 2008;27:649-58.
110. Blum CA, Selander C, Ruddy JM, et al. The incidence and clinical significance of pneumoperitoneum after percutaneous endoscopic gastrostomy: a review of 722 cases. *Am Surg* 2009;75:39-43.
111. Gottfried EB, Plumser AB, Clair MR. Pneumoperitoneum following percutaneous endoscopic gastrostomy. A prospective study. *Gastrointest Endosc* 1986;32:397-9.
112. Wiesen AJ, Sideridis K, Fernandes A, et al. True incidence and clinical significance of pneumoperitoneum after PEG placement: a prospective study. *Gastrointest Endosc* 2006;64:886-9.
113. Mamel JJ. Percutaneous endoscopic gastrostomy. *Am J Gastroenterol* 1989;84:703-10.
114. Fernandes ET, Hollabaugh R, Hixon SD, et al. Late presentation of gastrocolic fistula after percutaneous gastrostomy. *Gastrointest Endosc* 1988;34:368-9.
115. Maccabee DL, Dominitz JA, Lee SW, et al. Acute presentation of transverse colon injury following percutaneous endoscopic gastrostomy tube placement: case report and review of current management. *Surg Endosc* 2000;14:296.
116. Minocha A, Rupp TH, Jagers TL, et al. Silent colo-gastrocutaneous fistula as a complication of percutaneous endoscopic gastrostomy. *Am J Gastroenterol* 1994;89:2243-4.
117. Saltzberg DM, Anand K, Juvan P, et al. Colocutaneous fistula: an unusual complication of percutaneous endoscopic gastrostomy. *JPEN J Parenter Enteral Nutr* 1987;11:86-7.
118. Stefan MM, Holcomb GW, Ross AJ. Cologastric fistula as a complication of percutaneous endoscopic gastrostomy. *JPEN J Parenter Enteral Nutr* 1989;13:554-6.
119. Panos MZ, Reilly H, Moran A, et al. Percutaneous endoscopic gastrostomy in a general hospital: prospective evaluation of indications, outcome, and randomised comparison of two tube designs. *Gut* 1994;35:1551-6.
120. Bosco JJ, Barkun AN, Isenberg GA, et al. Endoscopic enteral nutritional access devices. *Gastrointest Endosc* 2002;56:796-802.
121. Foutch PG, Talbert GA, Waring JP, et al. Percutaneous endoscopic gastrostomy in patients with prior abdominal surgery: virtues of the safe tract. *Am J Gastroenterol* 1988;83:147-50.
122. Gauderer MW, Stellato TA. Gastrostomies: evolution, techniques, indications, and complications. *Curr Probl Surg* 1986;23:657-719.
123. Klein S, Heare BR, Soloway RD. The "buried bumper syndrome": a complication of percutaneous endoscopic gastrostomy. *Am J Gastroenterol* 1990;85:448-51.
124. Shallman RW, NorFleet RG, Hardache JM. Percutaneous endoscopic gastrostomy feeding tube migration and impaction in the abdominal wall. *Gastrointest Endosc* 1988;34:367-8.
125. Lee TH, Lin JT. Clinical manifestations and management of buried bumper syndrome in patients with percutaneous endoscopic gastrostomy. *Gastrointest Endosc* 2008;68:580-4.
126. Grant DG, Bradley PT, Pothier DD, et al. Complications following gastrostomy tube insertion in patients with head and neck cancer: a prospective multi-institution study, systematic review and meta-analysis. *Clin Otolaryngol* 2009;34:103-12.
127. Russell TR, Brotman M, Norris F. Percutaneous gastrostomy. A new simplified and cost-effective technique. *Am J Surg* 1984;148:132-7.
128. Behrle KM, Dekovich AA, Ammon HV. Spontaneous tube extrusion following percutaneous endoscopic gastrostomy. *Gastrointest Endosc* 1989;35:56-8.
129. DeLegge MH, Duckworth PF Jr, McHenry L Jr, et al. Percutaneous endoscopic gastrojejunostomy: a dual center safety and efficacy trial. *JPEN J Parenter Enteral Nutr* 1995;19:239-43.
130. DeLegge MH, Patrick P, Gibbs R. Percutaneous endoscopic gastrojejunostomy with a tapered tip, nonweighted jejunal feeding tube: improved placement success. *Am J Gastroenterol* 1996;91:1130-4.
131. Henderson JM, Strodel WE, Gilinsky NH. Limitations of percutaneous endoscopic jejunostomy. *JPEN J Parenter Enteral Nutr* 1993;17:546-50.
132. Maple JT, Petersen BT, Baron TH, et al. Direct percutaneous endoscopic jejunostomy: outcomes in 307 consecutive attempts. *Am J Gastroenterol* 2005;100:2681-8.
133. Shike M, Wallach C, Likier H. Direct percutaneous endoscopic jejunostomies. *Gastrointest Endosc* 1991;37:62-5.
134. Wolfsen HC, Kozarek RA, Ball TJ, et al. Tube dysfunction following percutaneous endoscopic gastrostomy and jejunostomy. *Gastrointest Endosc* 1990;36:261-3.
135. Zopf Y, Rabe C, Bruckmoser T, et al. Percutaneous endoscopic jejunostomy and jejunal extension tube through percutaneous endoscopic gastrostomy: a retrospective analysis of success, complications and outcome. *Digestion* 2009;79:92-7.
136. Muehldorfer SM, Stolte M, Martus P, et al. Diagnostic accuracy of forceps biopsy versus polypectomy for gastric polyps: a prospective multicentre study. *Gut* 2002;50:465-70.
137. Bardan E, Maor Y, Carter D, et al. Endoscopic ultrasound (EUS) before gastric polyp resection: is it mandatory? *J Clin Gastroenterol* 2007;41:371-4.
138. Hsieh YH, Lin HJ, Tseng GY, et al. Is submucosal epinephrine injection necessary before polypectomy? A prospective, comparative study. *Hepatogastroenterology* 2001;48:1379-82.
139. Lanza FL, Graham DY, Nelson RS, et al. Endoscopic upper gastrointestinal polypectomy. Report of 73 polypectomies in 63 patients. *Am J Gastroenterol* 1981;75:345-8.
140. Abbass R, Rigaux J, Al-Kawas FH. Nonampullary duodenal polyps: characteristics and endoscopic management. *Gastrointest Endosc* 2010;71:754-9.
141. Johnson MD, Mackey R, Brown N, et al. Outcome based on management for duodenal adenomas: sporadic versus familial disease. *J Gastrointest Surg* 2010;14:229-35.
142. Lepilliez V, Chemaly M, Ponchon T, et al. Endoscopic resection of sporadic duodenal adenomas: an efficient technique with a substantial risk of delayed bleeding. *Endoscopy* 2008;40:806-10.
143. Inoue H, Minami H, Kaga M, et al. Endoscopic mucosal resection and endoscopic submucosal dissection for esophageal dysplasia and carcinoma. *Gastrointest Endosc Clin N Am* 2010;20:25-34.
144. Cao Y, Liao C, Tan A, et al. Meta-analysis of endoscopic submucosal dissection versus endoscopic mucosal resection for tumors of the gastrointestinal tract. *Endoscopy* 2009;41:751-7.
145. Seewald S, Ang TL, Gotoda T, et al. Total endoscopic resection of Barrett esophagus. *Endoscopy* 2008;40:1016-20.
146. Oda I, Saito D, Tada M, et al. A multicenter retrospective study of endoscopic resection for early gastric cancer. *Gastric Cancer* 2006;9:262-70.
147. Ahmadi A, Draganov P. Endoscopic mucosal resection in the upper gastrointestinal tract. *World J Gastroenterol* 2008;14:1984-9.
148. Kakushima N, Fujishiro M. Endoscopic submucosal dissection for gastrointestinal neoplasms. *World J Gastroenterol* 2008;14:2962-7.
149. Kantsevov SV, Adler DG, Conway JD, et al. Endoscopic mucosal resection and endoscopic submucosal dissection. *Gastrointest Endosc* 2008;68:11-8.
150. Tamiya Y, Nakahara K, Kominato K, et al. Pneumomediastinum is a frequent but minor complication during esophageal endoscopic submucosal dissection. *Endoscopy* 2010;42:8-14.

151. Dulai GS, Jensen DM, Cortina G, et al. Randomized trial of argon plasma coagulation vs. multipolar electrocoagulation for ablation of Barrett's esophagus. *Gastrointest Endosc* 2005;61:232-40.
152. Luman W, Lessels AM, Palmer KR. Failure of Nd-YAG photocoagulation therapy as treatment for Barrett's oesophagus—a pilot study. *Eur J Gastroenterol Hepatol* 1996;8:627-30.
153. Michopoulos S, Tsibouris P, Bouzakis H, et al. Complete regression of Barrett's esophagus with heat probe thermocoagulation: mid-term results. *Gastrointest Endosc* 1999;50:165-72.
154. Sampliner RE, Faigel D, Fennerty MB, et al. Effective and safe endoscopic reversal of nondysplastic Barrett's esophagus with thermal electrocoagulation combined with high-dose acid inhibition: a multicenter study. *Gastrointest Endosc* 2001;53:554-8.
155. Rees JR, Lao-Sirieix P, Wong A, et al. Treatment for Barrett's oesophagus. *Cochrane Database Syst Rev* 2010(1):CD004060.
156. Manner H, May A, Miehke S, et al. Ablation of nonneoplastic Barrett's mucosa using argon plasma coagulation with concomitant esomeprazole therapy (APBANEX): a prospective multicenter evaluation. *Am J Gastroenterol* 2006;101:1762-9.
157. Petersen BT, Chuttani R, Croffie J, et al. Photodynamic therapy for gastrointestinal disease. *Gastrointest Endosc* 2006;63:927-32.
158. Overholt BF, Lightdale CJ, Wang KK, et al. Photodynamic therapy with porfimer sodium for ablation of high-grade dysplasia in Barrett's esophagus: international, partially blinded, randomized phase III trial. *Gastrointest Endosc* 2005;62:488-98.
159. Gross SA, Wolfsen HC. The role of photodynamic therapy in the esophagus. *Gastrointest Endosc Clin N Am* 2010;20:35-53.
160. Wolfsen HC. Present status of photodynamic therapy for high-grade dysplasia in Barrett's esophagus. *J Clin Gastroenterol* 2005;39:189-202.
161. Shaheen NJ, Sharma P, Overholt BF, et al. Radiofrequency ablation in Barrett's esophagus with dysplasia. *N Engl J Med* 2009;360:2277-88.
162. Pouw RE, Gondrie JJ, Van Vilsteren FGI, et al. Complications following circumferential radiofrequency energy ablation of Barrett's esophagus containing early neoplasia. *Gastrointest Endosc* 2008;67:AB145.
163. Lyday WD, Corbett FS, Kuperman DA, et al. Radiofrequency ablation of Barrett's esophagus: outcomes of 429 patients from a multicenter community practice registry. *Endoscopy* 2010;42:272-8.
164. Velanovich V. Endoscopic endoluminal radiofrequency ablation of Barrett's esophagus: initial results and lessons learned. *Surg Endosc* 2009;23:2175-80.
165. Vahabzadeh B, Rastogi A, Bansal A, et al. Use of a plastic endoprosthesis to successfully treat esophageal perforation following radiofrequency ablation of Barrett's esophagus. *Endoscopy* 2011;43:67-9.
166. Greenwald BD, Dumot JA, Abrams JA, et al. Endoscopic spray cryotherapy for esophageal cancer: safety and efficacy. *Gastrointest Endosc* 2010;71:686-93.
167. Greenwald BD, Dumot JA, Horwhat JD, et al. Safety, tolerability, and efficacy of endoscopic low-pressure liquid nitrogen spray cryotherapy in the esophagus. *Dis Esophagus* 2010;23:13-9.
168. Shaheen NJ, Greenwald BD, Peery AF, et al. Safety and efficacy of endoscopic spray cryotherapy for Barrett's esophagus with high-grade dysplasia. *Gastrointest Endosc* 2010;71:680-5.
169. Knyrim K, Wagner HJ, Bethge N, et al. A controlled trial of an expansile metal stent for palliation of esophageal obstruction due to inoperable cancer. *N Engl J Med* 1993;329:1302-7.
170. Shenfine J, McNamee P, Steen N, et al. A randomized controlled clinical trial of palliative therapies for patients with inoperable esophageal cancer. *Am J Gastroenterol* 2009;104:1674-85.
171. Jacobson BC, Hirota W, Baron TH, et al. The role of endoscopy in the assessment and treatment of esophageal cancer. *Gastrointest Endosc* 2003;57:817-22.
172. Kozarek RA, Ball TJ, Patterson DJ. Metallic self-expanding stent application in the upper gastrointestinal tract: caveats and concerns. *Gastrointest Endosc* 1992;38:1-6.
173. Tierney W, Chuttani R, Croffie J, et al. Enteral stents. *Gastrointest Endosc* 2006;63:920-6.
174. Baron TH. A practical guide for choosing an expandable metal stent for GI malignancies: is a stent by any other name still a stent? *Gastrointest Endosc* 2001;54:269-72.
175. Baron TH. Minimizing endoscopic complications: endoluminal stents. *Gastrointest Endosc Clin N Am* 2007;17:83-104.
176. Baron TH. Expandable metal stents for the treatment of cancerous obstruction of the gastrointestinal tract. *N Engl J Med* 2001;344:1681-7.
177. Siersema PD, Hop WC, van Blankenstein M, et al. A new design metal stent (Flamingo stent) for palliation of malignant dysphagia: a prospective study. The Rotterdam Esophageal Tumor Study Group. *Gastrointest Endosc* 2000;51:139-45.
178. Siersema PD, Tan TG, Sutorius FF, et al. Massive hemorrhage caused by a perforating Gianturco-Z stent resulting in an aorto-esophageal fistula. *Endoscopy* 1997;29:416-20.
179. Vlegaar FP, Siersema PD. Expandable stents for malignant esophageal disease. *Gastrointest Endosc Clin N Am* 2011;21:377-88.
180. Dua KS, Kozarek R, Kim J, et al. Self-expanding metal esophageal stent with anti-reflux mechanism. *Gastrointest Endosc* 2001;53:603-13.
181. Homs MY, Wahab PJ, Kuipers EJ, et al. Esophageal stents with antireflux valve for tumors of the distal esophagus and gastric cardia: a randomized trial. *Gastrointest Endosc* 2004;60:695-702.
182. Schembre DB. Recent advances in the use of stents for esophageal disease. *Gastrointest Endosc Clin N Am* 2010;20:103-21.
183. Wang MQ, Sze DY, Wang ZP, et al. Delayed complications after esophageal stent placement for treatment of malignant esophageal obstructions and esophagorespiratory fistulas. *J Vasc Interv Radiol* 2001;12:465-74.
184. Homs MY, Steyerberg EW, Kuipers EJ, et al. Causes and treatment of recurrent dysphagia after self-expanding metal stent placement for palliation of esophageal carcinoma. *Endoscopy* 2004;36:880-6.
185. Kinsman KJ, DeGregorio BT, Katon RM, et al. Prior radiation and chemotherapy increase the risk of life-threatening complications after insertion of metallic stents for esophagogastric malignancy. *Gastrointest Endosc* 1996;43:196-203.
186. Homs MY, Hansen BE, van Blankenstein M, et al. Prior radiation and/or chemotherapy has no effect on the outcome of metal stent placement for esophagogastric carcinoma. *Eur J Gastroenterol Hepatol* 2004;16:163-70.
187. Rajman I, Siddique I, Lynch P. Does chemoradiation therapy increase the incidence of complications with self-expanding coated stents in the management of malignant esophageal strictures? *Am J Gastroenterol* 1997;92:2192-6.
188. Gaidos JK, Draganov PV. Treatment of malignant gastric outlet obstruction with endoscopically placed self-expandable metal stents. *World J Gastroenterol* 2009;15:4365-71.
189. Maetani I, Ukita T, Tada T, et al. Metallic stents for gastric outlet obstruction: reintervention rate is lower with uncovered versus covered stents, despite similar outcomes. *Gastrointest Endosc* 2009;69:806-12.
190. Piesman M, Kozarek RA, Brandabur JJ, et al. Improved oral intake after palliative duodenal stenting for malignant obstruction: a prospective multicenter clinical trial. *Am J Gastroenterol* 2009;104:2404-11.
191. Lee KM, Choi SJ, Shin SJ, et al. Palliative treatment of malignant gastroduodenal obstruction with metallic stent: prospective comparison of covered and uncovered stents. *Scand J Gastroenterol* 2009;44:846-52.
192. Jeurnink SM, Steyerberg EW, van Hooft JE, et al. Surgical gastrojejunostomy or endoscopic stent placement for the palliation of malignant gastric outlet obstruction (SUSTENT study): a multicenter randomized trial. *Gastrointest Endosc* 2010;71:490-9.
193. Ly J, O'Grady G, Mittal A, et al. A systematic review of methods to palliate malignant gastric outlet obstruction. *Surg Endosc* 2010;24:290-7.
194. Laine L, Cook D. Endoscopic ligation compared with sclerotherapy for treatment of esophageal variceal bleeding. A meta-analysis. *Ann Intern Med* 1995;123:280-7.
195. Schuman BM, Beckman JW, Tedesco FJ, et al. Complications of endoscopic injection sclerotherapy: a review. *Am J Gastroenterol* 1987;82:823-30.
196. Piai G, Cipolletta L, Claar M, et al. Prophylactic sclerotherapy of high-risk esophageal varices: results of a multicentric prospective controlled trial. *Hepatology* 1988;8:1495-500.

197. Sarin SK, Nanda R, Sachdev G, et al. Intravariceal versus paravariceal sclerotherapy: a prospective, controlled, randomised trial. *Gut* 1987;28:657-62.
198. Sarin SK, Sachdev G, Nanda R, et al. Comparison of the two time schedules for endoscopic sclerotherapy: a prospective randomised controlled study. *Gut* 1986;27:710-3.
199. Westaby D, Melia WM, Macdougall BR, et al. Injection sclerotherapy for oesophageal varices: a prospective randomised trial of different treatment schedules. *Gut* 1984;25:129-32.
200. Polson RJ, Westaby D, Gimson AE, et al. Sucralfate for the prevention of early rebleeding following injection sclerotherapy for esophageal varices. *Hepatology* 1989;10:279-82.
201. Tabibian N, Smith JL, Graham DY. Sclerotherapy-associated esophageal ulcers: lessons from a double-blind, randomized comparison of sucralfate suspension versus placebo. *Gastrointest Endosc* 1989;35:312-5.
202. Tamura S, Shiozaki H, Kobayashi K, et al. Prospective randomized study on the effect of ranitidine against injection ulcer after endoscopic injection sclerotherapy for esophageal varices. *Am J Gastroenterol* 1991;86:477-80.
203. Johlin FC, Labrecque DR, Neil GA. Omeprazole heals mucosal ulcers associated with endoscopic injection sclerotherapy. *Dig Dis Sci* 1992;37:1373-6.
204. Shephard H, Barkin JS. Omeprazole heals mucosal ulcers associated with endoscopic injection sclerotherapy. *Gastrointest Endosc* 1993;39:474-5.
205. Krige JE, Bornman PC, Shaw JM, et al. Complications of endoscopic variceal therapy. *S Afr J Surg* 2005;43:177-88.
206. Krige JE, Shaw JM, Bornman PC, et al. Early rebleeding and death at 6 weeks in alcoholic cirrhotic patients with acute variceal bleeding treated with emergency endoscopic injection sclerotherapy. *S Afr J Surg* 2009;47:72-4.
207. Yuki M, Kazumori H, Yamamoto S, et al. Prognosis following endoscopic injection sclerotherapy for esophageal varices in adults: 20-year follow-up study. *Scand J Gastroenterol* 2008;43:1269-74.
208. Schmitz RJ, Sharma P, Badr AS, et al. Incidence and management of esophageal stricture formation, ulcer bleeding, perforation, and massive hematoma formation from sclerotherapy versus band ligation. *Am J Gastroenterol* 2001;96:437-41.
209. Koch H, Henning H, Grimm H, et al. Prophylactic sclerosing of esophageal varices--results of a prospective controlled study. *Endoscopy* 1986;18:40-3.
210. Stiegmann GV, Goff JS, Michaletz-Onody PA, et al. Endoscopic sclerotherapy as compared with endoscopic ligation for bleeding esophageal varices. *N Engl J Med* 1992;326:1527-32.
211. Sorensen T, Burcharth F, Pedersen ML, et al. Oesophageal stricture and dysphagia after endoscopic sclerotherapy for bleeding varices. *Gut* 1984;25:473-7.
212. The Copenhagen Esophageal Varices Sclerotherapy Project. Sclerotherapy after first variceal hemorrhage in cirrhosis. A randomized multicenter trial. *N Engl J Med* 1984;311:1594-600.
213. Korula J, Pandya K, Yamada S, et al. Perforation of esophagus after endoscopic variceal sclerotherapy. Incidence and clues to pathogenesis. *Dig Dis Sci* 1989;34:324-9.
214. Elfant AB, Peikin SR, Alexander JB, et al. Conservative management of endoscopic sclerotherapy-induced esophageal perforation. *Am Surg* 1994;60):985-7.
215. Iwase H, Suga S, Shimada M, et al. Eleven-year survey of safety and efficacy of endoscopic injection sclerotherapy using 2% sodium tetradecyl sulfate and contrast medium. *J Clin Gastroenterol* 1996;22:58-65.
216. Laine L, el-Newihi HM, Migikovsky B, et al. Endoscopic ligation compared with sclerotherapy for the treatment of bleeding esophageal varices. *Ann Intern Med* 1993;119:1-7.
217. Deboever G, Elegeert I, Defloor E. Portal and mesenteric venous thrombosis after endoscopic injection sclerotherapy. *Am J Gastroenterol* 1989;84:1336-7.
218. Stoltenberg PH, Goodale RL, Silvis SE. Portal vein thrombosis following combined endoscopic variceal sclerosis and vasopressin therapy for bleeding varices. *Am J Gastroenterol* 1987;82:1297-300.
219. Alexander S, Korman MG, Sievert W. Cyanoacrylate in the treatment of gastric varices complicated by multiple pulmonary emboli. *Intern Med J* 2006;36:462-5.
220. Neumann H, Scheidbach H, Mönkemüller K, et al. Multiple cyanoacrylate (Histoacryl) emboli after injection therapy of cardia varices. *Gastrointest Endosc* 2009;70:1025-6.
221. Garcia-Tsao G, Sanyal AJ, Grace ND, et al. Prevention and management of gastroesophageal varices and variceal hemorrhage in cirrhosis. *Hepatology* 2007;46:922-38.
222. Rerknimitr R, Chanyaswad J, Kongkam P, et al. Risk of bacteremia in bleeding and nonbleeding gastric varices after endoscopic injection of cyanoacrylate. *Endoscopy* 2008;40:644-9.
223. Sauerbruch T, Holl J, Ruckdeschel G, et al. Bacteremia associated with endoscopic sclerotherapy of oesophageal varices. *Endoscopy* 1985;17:170-2.
224. Lo GH, Lai KH, Cheng JS, et al. A prospective, randomized trial of sclerotherapy versus ligation in the management of bleeding esophageal varices. *Hepatology* 1995;22:466-71.
225. Young MF, Sanowski RA, Rasche R. Comparison and characterization of ulcerations induced by endoscopic ligation of esophageal varices versus endoscopic sclerotherapy. *Gastrointest Endosc* 1993;39:119-22.
226. Shaheen NJ, Stuart E, Schmitz SM, et al. Pantoprazole reduces the size of postbanding ulcers after variceal band ligation: a randomized, controlled trial. *Hepatology* 2005;41:588-94.
227. Rai RR, Nijhawan S, Singh G. Post-ligation stricture: a rare complication. *Endoscopy* 1996;28:406.
228. Cook DJ, Guyatt GH, Salena BJ, et al. Endoscopic therapy for acute nonvariceal upper gastrointestinal hemorrhage: a meta-analysis. *Gastroenterology* 1992;102:139-48.
229. Laine L, McQuaid KR. Endoscopic therapy for bleeding ulcers: an evidence-based approach based on meta-analyses of randomized controlled trials. *Clin Gastroenterol Hepatol* 2009;7:33-47.
230. Sung JJ, Tsoi KK, Ma TK, et al. Causes of mortality in patients with peptic ulcer bleeding: a prospective cohort study of 10,428 cases. *Am J Gastroenterol* 2010;105:84-9.
231. Lee KJ, Kim JH, Hahm KB, et al. Randomized trial of N-butyl-2-cyanoacrylate compared with injection of hypertonic saline-epinephrine in the endoscopic treatment of bleeding peptic ulcers. *Endoscopy* 2000;32:505-11.
232. Scharnke W, Hust MH, Braun B, et al. Complete gastric wall necrosis after endoscopic sclerotherapy for a gastric ulcer with visible arterial stump [in German]. *Dtsch Med Wochenschr* 1997;122:606-9.
233. Choudari CP, Palmer KR. Endoscopic injection therapy for bleeding peptic ulcer; a comparison of adrenaline alone with adrenaline plus ethanolamine oleate. *Gut* 1994;35:608-10.
234. Chung SS, Lau JY, Sung JJ, et al. Randomised comparison between adrenaline injection alone and adrenaline injection plus heat probe treatment for actively bleeding ulcers. *BMJ* 1997;314:1307-11.
235. Marmo R, Rotondano G, Piscopo R, et al. Dual therapy versus monotherapy in the endoscopic treatment of high-risk bleeding ulcers: a meta-analysis of controlled trials. *Am J Gastroenterol* 2007;102:279-89; quiz 469.
236. Rutgeerts P, Vantrappen G, Van Hootegem P, et al. Neodymium-YAG laser photocoagulation versus multipolar electrocoagulation for the treatment of severely bleeding ulcers: a randomized comparison. *Gastrointest Endosc* 1987;33:199-202.
237. Sung JJ, Tsoi KK, Lai LH, et al. Endoscopic clipping versus injection and thermo-coagulation in the treatment of non-variceal upper gastrointestinal bleeding: a meta-analysis. *Gut* 2007;56:1364-73.
238. Lau JY, Sung JJ, Lam YH, et al. Endoscopic retreatment compared with surgery in patients with recurrent bleeding after initial endoscopic control of bleeding ulcers. *N Engl J Med* 1999;340:751-6.
239. Laine L. Multipolar electrocoagulation in the treatment of active upper gastrointestinal tract hemorrhage. A prospective controlled trial. *N Engl J Med* 1987;316:1613-7.

240. Kapetanos D, Beltsis A, Chatzimavroudis G, et al. The use of endoclips in the treatment of nonvariceal gastrointestinal bleeding. *Surg Laparosc Endosc Percutan Tech* 2009;19:2-10.
241. Fujishiro M, Yahagi N, Nakamura M, et al. Safety of argon plasma coagulation for hemostasis during endoscopic mucosal resection. *Surg Laparosc Endosc Percutan Tech* 2006;16:137-40.
242. Choi KD, Jung HY, Lee GH, et al. Application of metal hemoclips for closure of endoscopic mucosal resection-induced ulcers of the stomach to prevent delayed bleeding. *Surg Endosc* 2008;22:1882-6.
243. Minami S, Gotoda T, Ono H, et al. Complete endoscopic closure of gastric perforation induced by endoscopic resection of early gastric cancer using endoclips can prevent surgery (with video). *Gastrointest Endosc* 2006;63:596-601.
244. Fujishiro M, Goto O, Kakushima N, et al. Endoscopic submucosal dissection of stomach neoplasms after unsuccessful endoscopic resection. *Dig Liver Dis* 2007;39:566-71.
245. Xin L, Liao Z, Jiang YP, et al. Indications, detectability, positive findings, total enteroscopy, and complications of diagnostic double-balloon enteroscopy: a systematic review of data over the first decade of use. *Gastrointest Endosc* 2011;74:563-70.
246. Mensink PB, Haringsma J, Kucharzik T, et al. Complications of double balloon enteroscopy: a multicenter survey. *Endoscopy* 2007;39:613-5.
247. Gerson LB, Tokar J, Chiorean M, et al. Complications associated with double balloon enteroscopy at nine US centers. *Clin Gastroenterol Hepatol* 2009;7:1177-82.
248. Heine GD, Hadithi M, Groenen MJ, et al. Double-balloon enteroscopy: indications, diagnostic yield, and complications in a series of 275 patients with suspected small-bowel disease. *Endoscopy* 2006;38:42-8.
249. Faigel DO, Pike IM, Baron TH, et al. Quality indicators for gastrointestinal endoscopic procedures: an introduction. *Gastrointest Endosc* 2006;63(4 Suppl):S3-9.

Prepared by:  
 ASGE STANDARDS OF PRACTICE COMMITTEE  
 Tamir Ben-Menachem, MD  
 G. Anton Decker, MBBCh, MHA, MRCP  
 Dayna S. Early, MD  
 Jerry Evans, MD  
 Robert D. Fanelli, MD  
 Deborah A. Fisher, MD, MHS  
 Laurel Fisher, MD  
 Norio Fukami, MD  
 Joo Ha Hwang, MD, PhD  
 Steven O. Ikenberry, MD  
 Rajeev Jain, MD  
 Terry L. Jue, MD  
 Khalid M. Khan, MD  
 Mary L. Krinsky, DO  
 Phyllis M. Malpas, MA, RN, CGRN, SGNA Representative  
 John T. Maple, DO  
 Ravi N. Sharaf, MD, MS  
 Jason A. Dominitz, MD, MHS, Previous Committee Chair  
 Brooks D. Cash, MD, Committee Chair

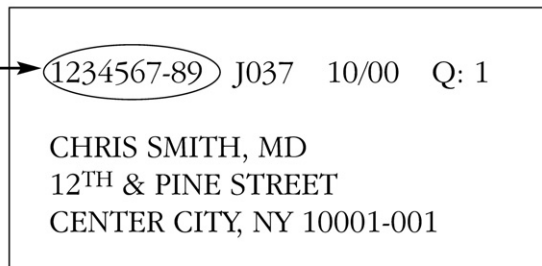
This document is a product of the ASGE Standards of Practice Committee. This document was reviewed and approved by the Governing Board of the ASGE.

Access to ***Gastrointestinal Endoscopy Online*** is reserved for all subscribers!

Full-text access to ***Gastrointestinal Endoscopy Online*** is available for all subscribers. ASGE MEMBER SUBSCRIBERS: To activate your individual online subscription, please visit <http://www.asge.org> and follow the instructions. NON-MEMBER SUBSCRIBERS: To activate your individual online subscription, please visit <http://www.giejournal.org> and follow the prompts to activate your *online access*. To activate your account, you will need your subscriber account/membership number, which you can find on your mailing label (*note*: the number of digits in your subscriber account number varies from 6 to 10 digits). See the example below in which the subscriber account number has been circled:

**Sample mailing label**

This is your Nonmember subscriber account number →



Personal subscriptions to ***Gastrointestinal Endoscopy Online*** are for individual use only and may not be transferred. Use of ***Gastrointestinal Endoscopy Online*** is subject to agreement to the terms and conditions as indicated online.