

The role of endoscopy in the evaluation and treatment of patients with biliary neoplasia

This is one of a series of statements discussing the use of GI endoscopy in common clinical situations. The Standards of Practice Committee of the American Society for Gastrointestinal Endoscopy (ASGE) prepared this text. This guideline is an update of a previous ASGE guideline published in 2005.¹ In preparing this guideline, a search of the medical literature was performed by using PubMed. Additional references were obtained from the bibliographies of the identified articles and from recommendations of expert consultants. When few or no data exist from well-designed prospective trials, emphasis is given to results from large series and reports from recognized experts. Guidelines for appropriate use of endoscopy are based on a critical review of the available data and expert consensus at the time that the guidelines are drafted. Further controlled clinical studies may be needed to clarify aspects of this guideline. This guideline may be revised as necessary to account for changes in technology, new data, or other aspects of clinical practice. The recommendations are based on reviewed studies and are graded on the strength of the supporting evidence (Table 1).² The strength of individual recommendations is based on both the aggregate evidence quality and an assessment of the anticipated benefits and harms. Weaker recommendations are indicated by phrases such as "We suggest," whereas stronger recommendations are typically stated as "We recommend."

This guideline is intended to be an educational device to provide information that may assist endoscopists in providing care to patients. This guideline is not a rule and should not be construed as establishing a legal standard of care or as encouraging, advocating, requiring, or discouraging any particular treatment. Clinical decisions in any particular case involve a complex analysis of the patient's condition and available courses of action. Therefore, clinical considerations may lead an endoscopist to take a course of action that varies from these guidelines.

INTRODUCTION

This document reviews the approach to the evaluation and treatment of the patient with suspected biliary neoplasia (Table 2). A discussion of the role of endoscopy for ampullary adenomas can be found in another ASGE document.¹

Patients with biliary neoplasia may present with abnormal imaging studies or serum chemistries or with symptoms such as jaundice, abdominal pain, anorexia, and weight loss. Elevations of bilirubin and alkaline phosphatase suggest biliary obstruction. A history of inflammatory bowel disease should be sought and a complete physical examination should be performed. Once there is clinical suspicion of biliary neoplasia, further investigation with abdominal imaging studies is appropriate. A chest x-ray or CT scan may also be appropriate to assist in diagnosis, staging, and therapeutic planning. Obtaining serum markers, such as CA 19-9 and carcinoembryonic antigen, may be considered, but their utility is controversial.^{3,4}

AMPULLARY ADENOCARCINOMA

Ampullary adenocarcinoma is usually suspected based on the demonstration of obstructive jaundice, often with dilation of the pancreatic and biliary ducts seen on abdominal imaging studies.⁵ Ampullary adenocarcinoma may present with bleeding and, if accompanied by jaundice, silver- or pewter-colored stool. Unlike pancreatic or biliary malignancies in which infection is rare, relapsing cholangitis is a presentation for ampullary adenocarcinoma. Rarely, patients may not be jaundiced and the tumor may be diagnosed incidentally at the time of EGD when biopsy samples can usually be more easily obtained with a side-viewing endoscope.

Transabdominal US (TUS) may demonstrate biliary duct dilation, but it is not sensitive for detecting ampullary tumors.⁶ Cross-sectional abdominal imaging, such as CT, magnetic resonance imaging (MRI), and magnetic resonance cholangiography (MRC), are useful for confirming dilation of the biliary and/or pancreatic ducts and staging more advanced disease,^{5,7} but are inferior to side-viewing endoscopy and EUS for detecting small ampullary lesions.⁶ Duodenoscopy by using a side-viewing endoscope permits direct visualization of the ampulla and tissue acquisition,^{1,8,9} and EUS permits diagnosis as well as staging via

TABLE 1. GRADE system for rating the quality of evidence for guidelines

Quality of evidence	Definition	Symbol
High quality	Further research is very unlikely to change our confidence in the estimate of effect	⊕⊕⊕⊕
Moderate quality	Further research is likely to have an important impact on our confidence in the estimate of effect and may change the estimate	⊕⊕⊕○
Low quality	Further research is very likely to have an important impact on our confidence in the estimate of effect and is likely to change the estimate	⊕⊕○○
Very low quality	Any estimate of effect is very uncertain	⊕○○○

TABLE 2. Biliary neoplasia

Primary
Ampullary neoplasia
Malignant
Ampullary adenocarcinoma
Benign
Ampullary adenoma
Biliary tract neoplasia
Malignant
Cholangiocarcinoma
Gallbladder polyps and gallbladder adenocarcinoma
Benign
Epithelial tumors
Adenomas, cystadenomas, papillomatosis
Endocrine
Nonepithelial
Metastatic
Unclassified
Lymphoma

FNA tissue sampling.¹⁰⁻¹² EUS and intraductal US (IDUS) can assess the depth of invasion in relation to the muscularis propria as well as intraductal extension and periampullary nodal involvement, facilitating selection of patients who can undergo surgical ampullectomy instead of pancreaticoduodenectomy.¹³ Although not endorsed for routine clinical management, endoscopic ampullectomy has been described for the removal of early ampullary adenocarcinomas.¹⁴ Once the lesion has been identified and staged, the techniques for palliation or surgical resection for cure are similar to the approach described for adenocarcinoma of the pancreatic head.¹⁵

BILIARY TRACT NEOPLASIA

Cholangiocarcinoma

Radiologic imaging A primary tumor of the bile duct should be suspected based on clinical and imaging findings. TUS, CT, or MRC may demonstrate biliary dilation with or without a stricture or mass. The differentiation of hilar versus nonhilar tumors is important because the approaches to surgical resection and endoscopic palliation differ depending on the location of the tumor. The Bismuth classification of cholangiocarcinoma is useful for determining surgical resectability and type of surgery (Fig. 1). Although TUS and CT may suggest cholangiocarcinoma, MRC offers advantages. MRC relies on the use of heavily T2-weighted image sequences that display fluid as high signal intensity to define the level of a biliary stricture and identify features suggestive of malignancy, such as a stricture length of more than 10 mm, irregular margins, and shouldering.^{16,17} MRC has a sensitivity of 77% to 86% and a specificity of 63% to 98% for the diagnosis of malignant biliary obstruction caused by cholangiocarcinoma.^{18,19}

Endoscopic approaches

ERCP. ERCP is important in the diagnosis and management of cholangiocarcinoma because tissue confirmation can be achieved with this technique. Brushings for cytology and biopsy samples for histology can confirm the diagnosis of cholangiocarcinoma. However, the sensitivity of these tests has been disappointing, ranging from 18% to 60%.^{20,21} Newer diagnostic tests, such as digital imaging analysis and fluorescence in situ hybridization, may offer increased sensitivity while maintaining the high specificity of cytology.²² Other techniques that use DNA-ploidy, such as flow cytometry, have been shown to improve the sensitivity of brush cytology while maintaining high specificity.²³ However, these technologies are not routinely available nor are they uniformly validated.

If the level of obstruction is located below the level of the bifurcation (Bismuth type I lesions, Fig. 1), surgical resection should be considered in medically stable patients without metastatic disease. If the patient is a poor surgical candidate, palliation with plastic or metal stents

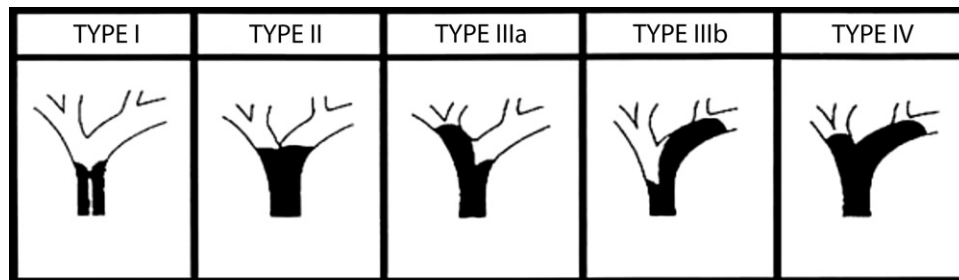


Figure 1. Bismuth classification of cholangiocarcinoma. Reprinted with permission from Cheng et al.¹¹⁵

should be considered. If the level of obstruction is at or above the hilum, extensive injection of contrast should be avoided to minimize the risk of postprocedural cholangitis because the entire biliary tree may not drain adequately.²⁴ MRC can be helpful in defining ductal anatomy before ERCP to reduce the risk of this adverse event.²⁵ Unilateral endoscopic biliary stent placement directed by prior imaging has been shown to achieve palliation of jaundice equal to that of bilateral stent placement, but with a lower risk of cholangitis^{26,27} and lower cost.²⁸ In 1 randomized trial, air cholangiography was found to be safer than and as effective as dye cholangiography in unilateral stent placement.²⁹ Similarly, recent meta-analyses have shown that wire-guided cannulation before contrast injection results in greater success of biliary cannulation and lower risk of post-ERCP pancreatitis.^{30,31}

Biliary stents are made of plastic or metal. Plastic stents are less expensive, but they occlude by a median of 3 to 6 months because of the deposition of bacterial biofilm.³² Self-expandable metal stents may be covered or uncovered and remain patent longer than plastic stents.³³ Although it has been suggested that the use of self-expandable metal stents be reserved for patients whose estimated survival is longer than 3 to 6 months,^{34,35} a recent Cochrane review concluded that the choice of stent type should be individualized.³⁶ In patients in whom ERCP is unsuccessful, interventional EUS techniques or percutaneous transhepatic cholangiography with stent placement can be considered where expertise is available.³⁷ Additional information on ERCP techniques and adverse events can be found in other ASGE practice guidelines.^{38,39}

Palliation of obstructive jaundice can be augmented through the use of photodynamic therapy (PDT) in patients with unresectable cholangiocarcinoma. Randomized clinical trials demonstrate improved biliary drainage and improved survival from a median of 98 to 210 days with stents alone to 498 to 630 days after both PDT and stenting.^{40,41} Retrospective comparisons of PDT with surgical palliation, stenting alone, and chemotherapy have demonstrated a survival benefit with PDT,^{42,43} and PDT has been used as neoadjuvant therapy for down-staging hilar cholangiocarcinomas to allow surgical resection.⁴⁴ Adverse events such as phototoxicity and cholangitis are common with PDT.⁴⁵ It should be noted that the only

agent available in the United States, Photofrin (porfimer sodium, Pinnacle Biologics, Inc., Bannockburn, IL), is expensive and not approved by the U.S. Food and Drug Administration for the treatment of cholangiocarcinoma. Catheter-based radiofrequency ablation is being evaluated for palliation of cholangiocarcinoma complementary to biliary stenting.^{46,47}

Cholangioscopy. Cholangioscopy allows identification of abnormalities commonly seen in biliary malignancy, such as dilated and tortuous blood vessels, villous mucosal projections, ulcerated strictures, and intraductal nodules.^{48,49} The addition of cholangioscopy-directed biopsies of biliary lesions may improve the diagnostic yield. Several case series report a sensitivity and specificity of approximately 90% for the diagnosis of cholangiocarcinoma with cholangioscopy.^{50,51} Tischendorf et al⁵² determined that cholangioscopy was superior to ERCP for detecting cholangiocarcinoma in patients with primary sclerosing cholangitis (PSC)-related dominant strictures. The sensitivity and specificity of cholangioscopy with biopsies were 92% and 93%, respectively. However, another study found disappointing results with cholangioscopy in the setting of PSC.⁵³ Additional data are needed to clarify the role of cholangioscopy in this situation. The recent development of single-operator cholangioscopes for peroral investigation of the bile duct may result in increased use of cholangioscopy beyond tertiary centers. However, ERCP with cholangioscopy may increase the risk of cholangitis compared with ERCP alone.⁵⁴⁻⁵⁶

EUS. Although MRC and ERCP are the primary methods for evaluating biliary strictures, EUS has an important role, particularly when other studies produce inconclusive findings. Several case series report that the sensitivity and specificity of EUS-guided FNA (EUS-FNA) for diagnosing extrahepatic cholangiocarcinoma is 53% to 89%.⁵⁷⁻⁶² DeWitt et al⁶³ reported that the sensitivity of EUS-FNA was 77% when performed in patients who had inconclusive biopsy samples and brushings obtained with ERCP. EUS-FNA has also been shown to be more accurate than CT or positron emission tomography for the evaluation of regional lymph node metastases in patients with cholangiocarcinoma.⁶⁴ It should be noted that some centers disqualify patients for liver transplantation after the performance

of EUS-FNA of the primary lesion because of concern of tumor seeding with this technique.⁶⁵

EUS may have a role in identifying early-stage cholangiocarcinoma. Sai et al⁶⁶ performed MRC on 142 nonicteric patients with an elevated alkaline phosphatase level and biliary dilation. Patients who had strictures or filling defects seen on MRC also underwent EUS examination. The combination of MRC and EUS improved the sensitivity and specificity for early cholangiocarcinoma from 80% to 90% and 90% to 98%, respectively, compared with MRC alone.

Intraductal ultrasound. IDUS at the time of ERCP may add useful information in the patient with suspected cholangiocarcinoma.^{67,68} IDUS is more accurate than ERCP-guided cytology and transpapillary biopsies for the identification of cholangiocarcinoma.^{69,70} IDUS is more accurate than standard EUS for staging hilar cholangiocarcinoma and when combined with cholangioscopy has an accuracy of 95% to 100% for staging hilar lesions.^{71,72} Three-dimensional reconstruction IDUS images may offer additional accuracy to standard IDUS and EUS.⁷³

Confocal laser endomicroscopy. Confocal laser endomicroscopy is an imaging technology that uses laser illumination to scan 1 focal plane and allows a microscopic view of the surface epithelium and as much as 250 μm of the lamina propria.⁷⁴ For biliary imaging, a confocal miniprobe is passed through the channel of a side-viewing endoscope and advanced into the biliary tree. This technology appears to have a useful role in differentiating benign from malignant biliary strictures,^{75,76} with performance characteristics to be determined by additional study.

Gallbladder polyps

Gallbladder polyps (GBPs) are detected in 4% to 7% of healthy subjects⁷⁷⁻⁷⁹ and the majority of GBPs are found incidentally on TUS, CT, or MRI. Most GBPs are not neoplastic. Gallbladder (GB) adenomas are the most common type of neoplastic GBP and can progress to adenocarcinoma of the GB. The goal of radiologic or endoscopic imaging is to differentiate the type and malignant potential of GBPs. TUS, CT, and EUS are excellent for estimating the location and size of GBPs, but are less accurate for determining the type of GBP. GBP size is an important predictor of gallbladder carcinoma.^{80,81} Symptomatic GBPs should be removed via cholecystectomy.⁸² There are no standard guidelines on the management of asymptomatic GBPs. Traditionally, cholecystectomy for polyps larger than 10 mm has been recommended. Recent studies have suggested that asymptomatic patients at risk of GB cancer (60 years of age and older, coexistence of gallstones, sessile morphology) with GBPs 6 mm or larger may benefit from cholecystectomy, but stronger evidence is required before this can be advocated.⁸²⁻⁸⁴ GBPs 6 mm or larger that are not removed should be followed by serial examinations, for example, every 12 months.⁷⁰⁻⁷⁴ Because GBPs are frequently malignant in patients with PSC, it has been pro-

posed that GBPs of any size in these patients should prompt cholecystectomy.^{85,86}

Radiologic imaging TUS can detect GBPs with high accuracy. Yang et al⁸⁷ reported a 90% sensitivity and 94% specificity for detecting GBPs. However, TUS is inaccurate for classifying the type of GBP.⁸⁸ Multiple studies with CT have shown that GBP size 10 mm or larger, sessile shape, and perception on unenhanced images are more common in neoplastic GBPs than non-neoplastic GBPs,^{89,90} but CT is also not accurate for differentiating benign from malignant GBPs,⁸⁹ thereby supporting the practice of cholecystectomy in patients with GBPs 10 mm or larger. Similar to CT, MRI features that favor a neoplastic etiology include sessile GBP and a diameter of 10 mm or larger.⁹¹

Endoscopic approaches

EUS. EUS is generally considered superior to other imaging modalities for differentiating neoplastic from non-neoplastic GBPs and detecting malignant GBPs,⁹² but the data are conflicting. In a study comparing TUS with EUS, Sugiyama et al⁹³ found that EUS determined the type of GBP more precisely than TUS (97% vs 71%). The authors described echogenic spots or a comet-tail artifact as pathognomonic for cholesterol polyps or adenomyomatosis, respectively. GBPs without these features predicted adenomas or adenocarcinomas. Sadamoto et al⁹⁴ found that 3 EUS variables predict neoplastic GBPs: (1) continuous maximum diameter of 11 mm or greater, (2) a heterogeneous internal echo pattern, and (3) absence of hyper-echoic spot(s). In contrast, Yang et al⁸⁷ found that TUS had a sensitivity of 90% for GB cancer compared with 86% with EUS and was superior to both CT and EUS for staging GB cancer.

Adenocarcinoma of the GB

Radiologic imaging. Adenocarcinoma of the GB is rare in Western countries, with an incidence of 1.2/100,000 in the United States.⁹⁵ In regions such as India, however, the incidence of GB cancer is as high as 21.5/100,000.⁹⁶ Compared with patients with benign GB conditions, TUS in patients with GB adenocarcinoma is more likely to demonstrate a solitary or displaced gallstone, GB-replacing or invasive mass, discontinuity of the mucosal echo, mural thickening or calcification, a mass or polyp 10 mm or larger, a fixed mass, loss of interface between the GB and liver, a porcelain GB, or direct liver invasion.^{97,98} GB adenocarcinoma is typically seen on CT as an infiltrating or polypoid mass or thickening of the GB wall.⁹⁹ For T staging of GB adenocarcinoma, the accuracy of CT has been reported to be 71% to 86%,^{100,101} and CT is poor for detecting nodal involvement.¹⁰² The sensitivity of MRI for nodal invasion of GB adenocarcinoma is 56% to 92% and 67% to 100% for local involvement.¹⁰³⁻¹⁰⁵

Endoscopic approaches

EUS. Because EUS facilitates close visualization of the GB, including the layers of the wall, its application in the

diagnosis and staging of GB adenocarcinoma is expanding.¹⁰⁶ After reviewing 39 patients with surgically resected GB cancer who had undergone preoperative EUS, Fujita et al¹⁰⁷ proposed an EUS staging system. Correlation of this system with histological depth of invasion demonstrated that type A tumors were confined to the mucosa (carcinoma in situ, Tis), type B tumors invaded varying depths between the mucosa and subserosa (T1-2), type C tumors invaded the subserosa or beyond (T2), and type D tumors invaded beyond the serosa (T3-4).¹⁰⁸ Jang et al⁹⁰ compared the performance of TUS, CT, and EUS in 144 patients with GBPs 10 mm or larger who underwent cholecystectomy and found that the diagnostic sensitivity for malignancy was comparable in TUS and EUS. The ability of EUS to predict nodal status in GB cancer has not been well studied. EUS can also be used for EUS-FNA of the GB wall where a sensitivity of 80% and specificity of 100% has been reported.⁵⁹

Benign neoplasia of biliary tract, metastatic disease, and lymphoma

The World Health Organization classifies benign tumors of the GB and extrahepatic bile ducts as epithelial tumors (eg, adenomas, cystadenomas, papillomatosis), endocrine tumors, and nonepithelial tumors. These tumors are rare and may mimic cholangiocarcinoma.¹⁰⁹ The endoscopic evaluation of these tumors is identical to that of cholangiocarcinoma or GB adenocarcinoma. Metastatic disease or lymphoma may lead to biliary obstruction, either intrinsically or extrinsically.^{110,111} MRC may be useful in establishing the level of obstruction and providing guidance for the clinician when biliary drainage is required.¹¹² Similar to primary neoplasia of the biliary tree, EUS and ERCP have important diagnostic and therapeutic roles in metastatic diseases or lymphoma of the biliary tract.¹¹³⁻¹¹⁵

RECOMMENDATIONS

- We recommend that EUS be performed in patients with suspected ampullary adenocarcinoma or cholangiocarcinoma if the EUS findings or positive FNA results would change management. ⊕⊕⊕○
- We recommend MRC to assess for resectability if a CT scan suggests cholangiocarcinoma, particularly of the bifurcation. If the lesion is unresectable, endoscopic palliation of jaundice should be performed by using MRC as a guide for unilateral drainage to minimize the risk of cholangitis. ⊕⊕⊕○
- We recommend ERCP to obtain tissue or facilitate further evaluation of indeterminate strictures. ⊕⊕⊕○
- We recommend that symptomatic patients with GBP undergo cholecystectomy. ⊕⊕⊕○
- We suggest that asymptomatic patients with a GBP larger than 10 mm undergo cholecystectomy. ⊕⊕○○
- We suggest that asymptomatic patients with a GBP 6 mm to 10 mm in size and without other risk factors for

GB cancer be followed by TUS every 12 months. ⊕⊕○○

- We recommend that the presence of any GBP should prompt cholecystectomy in patients with PSC. ⊕⊕⊕○

DISCLOSURE

The following author disclosed a financial relationship relevant to this publication: Dr D.A. Fisher, consultant to Epigemonics. The other authors disclosed no financial relationships relevant to this publication.

Abbreviations: EUS-FNA, EUS-guided FNA; GB, gallbladder; GBP, gallbladder polyp; IDUS, intraductal US; MRC, magnetic resonance cholangiography; MRI, magnetic resonance imaging; PSC, primary sclerosing cholangitis; PDT, photodynamic therapy; TUS, transabdominal ultrasound.

REFERENCES

1. Adler DG, Baron TH, Davila RE, et al. The role of endoscopy in ampullary and duodenal adenomas. *Gastrointest Endosc* 2005;62:1-8.
2. Guyatt GH, Oxman AD, Vist GE, et al. GRADE: an emerging consensus on rating quality of evidence and strength of recommendations. *BMJ* 2008;336:924-6.
3. Patel AH, Harnois DM, Klee GG, et al. The utility of CA 19-9 in the diagnosis of cholangiocarcinoma in patients without primary sclerosing cholangitis. *Am J Gastroenterol* 2000;95:204-7.
4. Steinberg WM, Gelfand R, Anderson KK, et al. Comparison of the sensitivity and specificity of the CA19-9 and carcinoembryonic antigen assays in detecting cancer of the pancreas. *Gastroenterology* 1986;90:343-9.
5. Tsukada K, Takada T, Miyazaki M, et al. Diagnosis of biliary tract and ampullary carcinomas. *J Hepatobiliary Pancreat Surg* 2008;15:31-40.
6. Chen W-X, Xie Q-G, Zhang W-F, et al. Multiple imaging techniques in the diagnosis of ampullary carcinoma. *Hepatobiliary Pancreat Dis Int* 2008;7:649-53.
7. Irie H, Honda H, Shinozaki K, et al. MR imaging of ampullary carcinomas. *J Comput Assist Tomogr* 2002;26:711-7.
8. Cohen S, Bacon BR, Berlin JA, et al. National Institutes of Health State-of-the-Science Conference Statement: ERCP for diagnosis and therapy, January 14-16, 2002. *Gastrointest Endosc* 2002;56:803-9.
9. Menzel J, Poremba C, Dietl KH, et al. Tumors of the papilla of Vater—inadequate diagnostic impact of endoscopic forceps biopsies taken prior to and following sphincterotomy. *Ann Oncol* 1999;10:1227-31.
10. Mallery JS, Centeno BA, Hahn PF, et al. Pancreatic tissue sampling guided by EUS, CT/US, and surgery: a comparison of sensitivity and specificity. *Gastrointest Endosc* 2002;56:218-24.
11. Rosch T, Braig C, Gain T, et al. Staging of pancreatic and ampullary carcinoma by endoscopic ultrasonography. Comparison with conventional sonography, computed tomography, and angiography. *Gastroenterology* 1992;102:188-99.
12. Tierney WM, Francis IR, Eckhauser F, et al. The accuracy of EUS and helical CT in the assessment of vascular invasion by peripapillary malignancy. *Gastrointest Endosc* 2001;53:182-8.
13. Quirk DM, Rattner DW, Fernandez-del Castillo C, et al. The use of endoscopic ultrasonography to reduce the cost of treating ampullary tumors. *Gastrointest Endosc* 1997;46:334-7.
14. Hernandez LV, Catalano MF. Endoscopic papillectomy. *Curr Opin Gastroenterol* 2008;24:617-22.
15. Baron TH, Mallery JS, Hirota WK, et al. The role of endoscopy in the evaluation and treatment of patients with pancreaticobiliary malignancy. *Gastrointest Endosc* 2003;58:643-9.

16. Mesurur Halefoglou A. Magnetic resonance cholangiopancreatography. *Semin Roentgenol* 2008;43:282-9.
17. Park M-S, Kim TK, Kim KW, et al. Differentiation of extrahepatic bile duct cholangiocarcinoma from benign stricture: findings at MRCP versus ERCP. *Radiology* 2004;233:234-40.
18. Guibaud L, Bret PM, Reinhold C, et al. Bile duct obstruction and chole-docholithiasis: diagnosis with MR cholangiography. *Radiology* 1995; 197:109-15.
19. Rosch T, Meining A, Fruhmorgen S, et al. A prospective comparison of the diagnostic accuracy of ERCP, MRCP, CT, and EUS in biliary strictures. *Gastrointest Endosc* 2002;55:870-6.
20. De Bellis M, Sherman S, Fogel EL, et al. Tissue sampling at ERCP in suspected malignant biliary strictures (Part 1). *Gastrointest Endosc* 2002;56:552-61.
21. Fogel EL, De Bellis M, McHenry L, et al. Effectiveness of a new long cytology brush in the evaluation of malignant biliary obstruction: a prospective study. *Gastrointest Endosc* 2006;63:71-7.
22. Moreno Luna LE, Kipp B, Halling KC, et al. Advanced cytologic techniques for the detection of malignant pancreaticobiliary strictures. *Gastroenterology* 2006;131:1064-72.
23. Lindberg B, Enochsson L, Tribukait B, et al. Diagnostic and prognostic implications of DNA ploidy and S-phase evaluation in the assessment of malignancy in biliary strictures. *Endoscopy* 2006;38:561-5.
24. Chang WH, Kortan P, Haber GB. Outcome in patients with bifurcation tumors who undergo unilateral versus bilateral hepatic duct drainage. *Gastrointest Endosc* 1998;47:354-62.
25. Lee SS, Kim MH, Lee SK, et al. MR cholangiography versus cholangioscopy for evaluation of longitudinal extension of hilar cholangiocarcinoma. *Gastrointest Endosc* 2002;56:25-32.
26. Hintze RE, Abou-Rebyeh H, Adler A, et al. Magnetic resonance cholangiopancreatography-guided unilateral endoscopic stent placement for Klatskin tumors. *Gastrointest Endosc* 2001;53:40-6.
27. De Palma GD, Galloro G, Siciliano S, et al. Unilateral versus bilateral endoscopic hepatic duct drainage in patients with malignant hilar biliary obstruction: results of a prospective, randomized, and controlled study. *Gastrointest Endosc* 2001;53:547-53.
28. Harewood GC, Baron TH. Cost analysis of magnetic resonance cholangiography in the management of inoperable hilar biliary obstruction. *Am J Gastroenterol* 2002;97:1152-8.
29. Sud R, Puri R, Jain PK, et al. Air cholangiogram is not inferior to dye cholangiogram: A randomized study [abstract]. *Gastrointest Endosc* 2011;73:AB347-8.
30. Cennamo V, Fuccio L, Zagari RM, et al. Can a wire-guided cannulation technique increase bile duct cannulation rate and prevent post-ERCP pancreatitis? A meta-analysis of randomized controlled trials. *Am J Gastroenterol* 2009;104:2343-50.
31. Shao LM, Chen QY, Chen MY, et al. Can wire-guided cannulation reduce the risk of post-endoscopic retrograde cholangiopancreatography pancreatitis? A meta-analysis of randomized controlled trials. *J Gastroenterol Hepatol* 2009;54:1710-5.
32. Baron TH. Palliation of malignant obstructive jaundice. *Gastroenterol Clin North Am* 2006;35:101-12.
33. Davids PH, Groen AK, Rauws EA, et al. Randomised trial of self-expanding metal stents versus polyethylene stents for distal malignant biliary obstruction. *Lancet* 1992;340:1488-92.
34. Yeoh KG, Zimmerman MJ, Cunningham JT, et al. Comparative costs of metal versus plastic biliary stent strategies for malignant obstructive jaundice by decision analysis. *Gastrointest Endosc* 1999;49:466-71.
35. Kaassis M, Boyer J, Dumas R, et al. Plastic or metal stents for malignant stricture of the common bile duct? Results of a randomized prospective study. *Gastrointest Endosc* 2003;57:178-82.
36. Moss AC, Morris E, Mac Mathuna P. Palliative biliary stents for obstructing pancreatic carcinoma. Update in Cochrane Database Syst Rev 2006;(2):CD004200.
37. Kaul V, Adler DG, Conway JD, et al. Interventional EUS. *Gastrointest Endosc* 2010;72:1-4.
38. Adler DG, Baron TH, Davila RE, et al. ASGE guideline: the role of ERCP in diseases of the biliary tract and the pancreas. *Gastrointest Endosc* 2005;62:1-8.
39. Anderson MA, Fisher L, Jain R, et al. Complications of ERCP. *Gastrointest Endosc* 2012;75:467-73.
40. Ortner ME, Caca K, Berr F, et al. Successful photodynamic therapy for nonresectable cholangiocarcinoma: a randomized prospective study. *Gastroenterology* 2003;125:1355-63.
41. Zoepf T, Jakobs R, Arnold JC, et al. Palliation of nonresectable bile duct cancer: improved survival after photodynamic therapy. *Am J Gastroenterol* 2005;100:2426-30.
42. Witzigmann H, Berr F, Ringel U, et al. Surgical and palliative management and outcome in 184 patients with hilar cholangiocarcinoma: palliative photodynamic therapy plus stenting is comparable to r1/r2 resection. *Ann Surg* 2006;244:230-9.
43. Kahaleh M, Mishra R, Shami VM, et al. Unresectable cholangiocarcinoma: comparison of survival in biliary stenting alone versus stenting with photodynamic therapy. *Clin Gastroenterol Hepatol* 2008;6:290-7.
44. Wiedmann M, Caca K, Berr F, et al. Neoadjuvant photodynamic therapy as a new approach to treating hilar cholangiocarcinoma: a phase II pilot study. *Cancer* 2003;97:2783-90.
45. Aljiffry M, Walsh MJ, Molinari M. Advances in diagnosis, treatment and palliation of cholangiocarcinoma: 1990-2009. *World J Gastroenterol* 2009;15:4240-62.
46. Monga A, Gupta R, Ramchandani M, et al. Endoscopic radiofrequency ablation of cholangiocarcinoma: new palliative treatment modality (with videos). *Gastrointest Endosc* 2011;74:935-7.
47. Steel AW, Postgate AJ, Khorsandi S, et al. Endoscopically applied radio-frequency ablation appears to be safe in the treatment of malignant biliary obstruction. *Gastrointest Endosc* 2011;73:149-53.
48. Seo DW, Lee SK, Yoo KS, et al. Cholangioscopic findings in bile duct tumors. *Gastrointest Endosc* 2000;52:630-4.
49. Kim HJ, Kim MH, Lee SK, et al. Tumor vessel: a valuable cholangioscopic clue of malignant biliary stricture. *Gastrointest Endosc* 2000;52:635-8.
50. Langer DA, Shah RJ, Chen YK. The role of cholangiopancreatography (CP) and cholangioscopic forceps biopsy (CFB) in the management of pancreaticobiliary (PB) diseases [abstract]. *Gastrointest Endosc* 2002;55: 93.
51. Shah RJ, Langer DA, Antillon MR, et al. Cholangioscopy and cholangioscopic forceps biopsy in patients with indeterminate pancreaticobiliary pathology. *Clin Gastroenterol Hepatol* 2006;4:219-25.
52. Tischendorf JJ, Kruger M, Trautwein C, et al. Cholangioscopic characterization of dominant bile duct stenoses in patients with primary sclerosing cholangitis. *Endoscopy* 2006;38:665-9.
53. Awadallah NS, Chen YK, Piraka C, et al. Is there a role for cholangioscopy in patients with primary sclerosing cholangitis? *Am J Gastroenterol* 2006;101:284-91.
54. Ross AS, Kozarek RA. Cholangioscopy: where are we now? *Curr Opin Gastroenterol* 2009;25:245-51.
55. Chen YK, Pleskow DK. SpyGlass single-operator peroral cholangiopancreatography system for the diagnosis and therapy of bile-duct disorders: a clinical feasibility study (with video). *Gastrointest Endosc* 2007; 65:832-41.
56. Sethi A, Chen YK, Austin GL, et al. ERCP with cholangiopancreatography may be associated with higher rates of complications than ERCP alone: a single-center experience. *Gastrointest Endosc* 2011;73:251-6.
57. Fritscher-Ravens A, Broering DC, Knoefel WT, et al. EUS-guided fine-needle aspiration of suspected hilar cholangiocarcinoma in potentially operable patients with negative brush cytology. *Am J Gastroenterol* 2004;99:45-51.
58. Lee JH, Salem R, Aslanian H, et al. Endoscopic ultrasound and fine-needle aspiration of unexplained bile duct strictures. *Am J Gastroenterol* 2004;99:1069-73.
59. Meara RS, Jhala D, Eloubeidi MA, et al. Endoscopic ultrasound-guided FNA biopsy of bile duct and gallbladder: analysis of 53 cases. *Cytopathology* 2006;17:42-9.

60. Rosch T, Hofrichter K, Frimberger E, et al. ERCP or EUS for tissue diagnosis of biliary strictures? A prospective comparative study. *Gastrointest Endosc* 2004;60:390-6.
61. Fritscher-Ravens A, Broering DC, Sriram PV, et al. EUS-guided fine-needle aspiration cytodiagnosis of hilar cholangiocarcinoma: a case series. *Gastrointest Endosc* 2000;52:534-40.
62. Eloubeidi MA, Chen VK, Jhala NC, et al. Endoscopic ultrasound-guided fine needle aspiration biopsy of suspected cholangiocarcinoma. *Clin Gastroenterol Hepatol* 2004;2:209-13.
63. DeWitt J, Misra VL, Leblanc JK, et al. EUS-guided FNA of proximal biliary strictures after negative ERCP brush cytology results. *Gastrointest Endosc* 2006;64:325-33.
64. Gleeson FC, Rajan E, Levy MJ, et al. EUS-guided FNA of regional lymph nodes in patients with unresectable hilar cholangiocarcinoma. *Gastrointest Endosc* 2008;67:438-43.
65. Heimbach JK, Sanchez W, Rosen CB, et al. Trans-peritoneal fine needle aspiration biopsy of hilar cholangiocarcinoma is associated with disease dissemination. *HPB (Oxford)* 2011;13:356-60.
66. Sai JK, Suyama M, Kubokawa Y, et al. Early detection of extrahepatic bile-duct carcinomas in the nonicteric stage by using MRCP followed by EUS. *Gastrointest Endosc* 2009;70:29-36.
67. Hawes RH. Diagnostic and therapeutic uses of ERCP in pancreatic and biliary tract malignancies. *Gastrointest Endosc* 2002;56:S201-5.
68. Vazquez-Sequeiros E, Baron TH, Clain JE, et al. Evaluation of indeterminate bile duct strictures by intraductal US. *Gastrointest Endosc* 2002;56:372-9.
69. Domagk D, Poremba C, Dietl KH, et al. Endoscopic transpapillary biopsies and intraductal ultrasonography in the diagnostics of bile duct strictures: a prospective study. *Gut* 2002;51:240-4.
70. Tamada K, Tomiyama T, Wada S, et al. Endoscopic transpapillary bile duct biopsy with the combination of intraductal ultrasonography in the diagnosis of biliary strictures. *Gut* 2002;50:326-31.
71. Menzel J, Poremba C, Dietl KH, et al. Preoperative diagnosis of bile duct strictures—comparison of intraductal ultrasonography with conventional endosonography. *Scand J Gastroenterol* 2000;35:77-82.
72. Kim HM, Park JY, Kim KS, et al. Intraductal ultrasonography combined with percutaneous transhepatic cholangioscopy for the preoperative evaluation of longitudinal tumor extent in hilar cholangiocarcinoma. *J Gastroenterol Hepatol* 2010;25:286-92.
73. Inui K, Miyoshi H, Yoshino J. Bile duct cancers: what can EUS offer? Intraductal US, 3D-IDUS? FNA—is it possible? *Endoscopy* 2006;38(Suppl 1):S47-9.
74. Othman MO, Wallace MB. Confocal laser endomicroscopy: is it prime time? *J Clin Gastroenterol* 2011;45:205-6.
75. Loeser CS, Robert ME, Mennone A, et al. Confocal endomicroscopic examination of malignant biliary strictures and histologic correlation with lymphatics. *J Clin Gastroenterol* 2011;45:246-52.
76. Meining A, Frimberger E, Becker V, et al. Detection of cholangiocarcinoma in vivo using miniprobe-based confocal fluorescence microscopy. *Clin Gastroenterol Hepatol* 2008;6:1057-60.
77. Akatsu T, Aiura K, Shimazu M, et al. Can endoscopic ultrasonography differentiate nonneoplastic from neoplastic gallbladder polyps? *Dig Dis Sci* 2006;51:416-21.
78. Jorgensen T, Jensen KH, Jorgensen T, et al. Polyps in the gallbladder. A prevalence study. *Scand J Gastroenterol* 1990;25:281-6.
79. Chen CY, Lu CL, Chang FY, et al. Risk factors for gallbladder polyps in the Chinese population. *Am J Gastroenterol* 1997;92:2066-8.
80. Sheth S, Bedford A, Chopra S. Primary gallbladder cancer: recognition of risk factors and the role of prophylactic cholecystectomy. *Am J Gastroenterol* 2000;95:1402-10.
81. Koga A, Watanabe K, Fukuyama T, et al. Diagnosis and operative indications for polypoid lesions of the gallbladder. *Arch Surg* 1988;123:26-9.
82. Gallahan WC, Conway JD. Diagnosis and management of gallbladder polyps. *Gastroenterol Clin N Am* 2010;39:359-67.
83. Zielinski MD, Atwell TD, Davis PW, et al. Comparison of surgically resected polypoid lesions of the gallbladder to their pre-operative ultrasound characteristics. *J Gastrointest Surg* 2009;13:19-25.
84. Park JY, Hong SP, Kim YJ, et al. Long-term follow up of gallbladder polyps. *J Gastroenterol Hepatol* 2009;24:219-22.
85. Buckles DC, Lindor KD, LaRusso NF, et al. In primary sclerosing cholangitis, gallbladder polyps are frequently malignant. *Am J Gastroenterol* 2002;97:1138-42.
86. Leung UC, Wong PY, Roberts RH, et al. Gall bladder polyps in sclerosing cholangitis: does the 1-cm rule apply? *ANZ J Surg* 2007;77:355-7.
87. Yang HL, Sun YG, Wang Z, et al. Polypoid lesions of the gallbladder: diagnosis and indications for surgery. *Br J Surg* 1992;79:227-9.
88. Akyurek N, Salman B, Irkorucu O, et al. Ultrasonography in the diagnosis of true gallbladder polyps: the contradiction in the literature. *HPB (Oxford)* 2005;7:155-8.
89. Park KW, Kim SH, Choi SH, et al. Differentiation of nonneoplastic and neoplastic gallbladder polyps 1 cm or bigger with multi-detector row computed tomography. *J Comput Assist Tomogr* 2010;34:135-9.
90. Jang JY, Kim SW, Lee SE, et al. Differential diagnostic and staging accuracies of high resolution ultrasonography, endoscopic ultrasonography, and multidetector computed tomography for gallbladder polypoid lesions and gallbladder cancer. *Ann Surg* 2009;250:943-9.
91. Elsayer KM, Oliveira EP, Narra VR, et al. Magnetic resonance imaging of the gallbladder: spectrum of abnormalities. *Acta Radiol* 2007;48:476-82.
92. Schwartz D, Wiersema M. The role of endoscopic ultrasound in hepatobiliary disease. *Curr Gastroenterol Rep* 2002;4:72-8.
93. Sugiyama M, Xie XY, Atomi Y, et al. Differential diagnosis of small polypoid lesions of the gallbladder: the value of endoscopic ultrasonography. *Ann Surg* 1999;229:498-504.
94. Sadamoto Y, Oda S, Tanaka M, et al. A useful approach to the differential diagnosis of small polypoid lesions of the gallbladder, utilizing an endoscopic ultrasound scoring system. *Endoscopy* 2002;34:959-65.
95. Duffy A, Capanu M, Abou-Alfa G, et al. Gallbladder cancer (GBC): 10-year experience at Memorial Sloan-Kettering Cancer Centre (MSKCC). *J Surg Oncol* 2008;98:485-9.
96. Aldouri AQ, Malik HZ, Waytt J, et al. The risk of gallbladder cancer from polyps in a large multiethnic series. *Eur J Surg Oncol* 2009;35:48-51.
97. Wibbenmeyer LA, Sharafuddin MJ, Wolverson MK, et al. Sonographic diagnosis of unsuspected gallbladder cancer: imaging findings in comparison with benign gallbladder conditions. *AJR Am J Roentgenol* 1995;165:1169-74.
98. Rodríguez-Fernández A, Gómez-Río M, Medina-Benítez A, et al. Application of modern imaging methods in diagnosis of gallbladder cancer. *J Surg Oncol* 2006;93:650-64.
99. Kumar A, Agarwal S. Carcinoma of the gallbladder: CT findings in 50 cases. *Abdom Imaging* 1994;19:304-8.
100. Kim BS, Ha HK, Lee IJ, et al. Accuracy of CT in local staging of gallbladder carcinoma. *Acta Radiol* 2002;43:71-6.
101. Yoshimitsu K, Honda H, Shinozaki K, et al. Helical CT of the local spread of carcinoma of the gallbladder: evaluation according to the TNM system in patients who underwent surgical resection. *AJR Am J Roentgenol* 2002;179:423-8.
102. Ohtani T, Shirai Y, Tsukada K, et al. Spread of gallbladder carcinoma: CT evaluation with pathologic correlation. *Abdom Imaging* 1996;21:195-201.
103. Tseng J-H, Wan Y-L, Hung C-F, et al. Diagnosis and staging of gallbladder carcinoma: Evaluation with dynamic MR imaging. *Clin Imaging* 2002;26:177-82.
104. Schwartz LH, Black J, Fong Y, et al. Gallbladder carcinoma: findings at MR imaging with MR cholangiopancreatography. *J Comput Assist Tomogr* 2002;26:405-10.
105. Kim JH, Kim TK, Eun HW, et al. Preoperative evaluation of gallbladder carcinoma: efficacy of combined use of MR imaging, MR cholangiography, and contrast-enhanced dual-phase three-dimensional MR angiography. *J Magn Reson Imaging* 2002;16:676-84.

106. O'Neill DER, Saunders MD. Endoscopic ultrasonography in diseases of the gallbladder. *Gastroenterol Clin N Am* 2010;39:289-305.

107. Fujita N, Noda Y, Kobayashi G, et al. Diagnosis of the depth of invasion of gallbladder carcinoma by EUS. *Gastrointest Endosc* 1999;50:659-63.

108. Sadamoto Y, Kubo H, Harada N, et al. Preoperative diagnosis and staging of gallbladder carcinoma by EUS. *Gastrointest Endosc* 2003;58:536-41.

109. Fletcher ND, Wise PE, Sharp KW. Common bile duct papillary adenoma causing obstructive jaundice: case report and review of the literature. *Am Surg* 2004;70:448-52.

110. Penn I. Primary malignancies of the hepato-biliary-pancreatic system in organ allograft recipients. *J Hepatobiliary Pancreat Surg* 1998;5:157-64.

111. Espanol T, de Gracia J, Caragol I, et al. Malignancies in primary immunodeficient patients. *Immunodeficiency* 1993;4:197-9.

112. Yeh TS, Jan YY, Tseng JH, et al. Malignant perihilar biliary obstruction: magnetic resonance cholangiopancreatographic findings. *Am J Gastroenterol* 2000;95:432-40.

113. Gan SI, Rajan E, Adler DG, et al. Role of EUS. *Gastrointest Endosc* 2007;66:425-34.

114. Jacobson BC, Baron TH, Adler DG, et al. ASGE guideline: the role of endoscopy in the diagnosis and the management of cystic lesions and inflammatory fluid collections of the pancreas. *Gastrointest Endosc* 2005;61:363-70.

115. Cheng JL, Bruno MJ, Bergman JJ, et al. Endoscopic palliation of patients with biliary obstruction caused by nonresectable hilar cholangiocarcinoma: efficacy of self-expandable metallic Wallstents. *Gastrointest Endosc* 2002;56:33-9.

Prepared by:
ASGE STANDARDS OF PRACTICE COMMITTEE
Michelle A. Anderson, MD
Vasu Appalaneni, MD
Tamir Ben-Menachem, MD
G. Anton Decker, MD
Dayna S. Early, MD
John A. Evans, MD
Robert D. Fanelli, MD
Deborah A. Fisher, MD
Laurel R. Fisher, MD
Norio Fukami, MD
Joo Ha Hwang, MD, PhD
Steven O. Ikenberry, MD
Rajeev Jain, MD
Terry L. Jue, MD
Khalid Khan, MD, NASPAGHAN Representative
Mary Lee Krinsky, DO
Phyllis M. Malpas, MA, RN, SGNA Representative
John T. Maple, DO
Ravi N. Sharaf, MD
Amandeep K. Shergill, MD
Jason A. Dominitz, MD, MHS (Previous Chair)
Brooks D. Cash, MD (Chair)

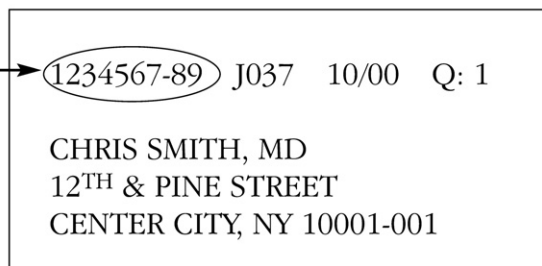
This document is a product of the ASGE Standards of Practice Committee. This document was reviewed and approved by the Governing Board of the ASGE.

Access to ***Gastrointestinal Endoscopy Online*** is reserved for all subscribers!

Full-text access to ***Gastrointestinal Endoscopy Online*** is available for all subscribers. ASGE MEMBER SUBSCRIBERS: To activate your individual online subscription, please visit <http://www.asge.org> and follow the instructions. NON-MEMBER SUBSCRIBERS: To activate your individual online subscription, please visit <http://www.giejournal.org> and follow the prompts to activate your *online access*. To activate your account, you will need your subscriber account/membership number, which you can find on your mailing label (*note*: the number of digits in your subscriber account number varies from 6 to 10 digits). See the example below in which the subscriber account number has been circled:

Sample mailing label

This is your Nonmember subscriber account number →



Personal subscriptions to ***Gastrointestinal Endoscopy Online*** are for individual use only and may not be transferred. Use of ***Gastrointestinal Endoscopy Online*** is subject to agreement to the terms and conditions as indicated online.